

NEUROIMAGING IN EPILEPSY



PUNJAMA LERTBUTSAYANUKUL, MD.
NEURORADIOLOGY DEPARTMENT
PRASAT NEUROLOGICAL INSTITUTE



NEUROIMAGING IN EPILEPSY

- Computed tomography (CT)
- Magnetic resonance imaging (MRI) : Structural and functional MRI (fMRI), MR spectroscopy (MRS), MR perfusion
- EEG combined with fMRI (EEG/fMRI)
- Positron emission tomography (PET)
- Ictal and interictal single photon emission computed tomography (SPECT)
- Magnetoencephalography (MEG)
- Wada Test (Cerebral angiography)

ANATOMIC NEUROIMAGING (MRI, CT)

- Determination of the actual pathologic/structural lesion
- Determination of location and extent of the potential epileptogenic zone
- Surgical planning (type of resection or palliative surgery)
- Predicting operative outcome

FUNCTIONAL NEUROIMAGING (PET, SPECT, FMRI, EEG/FMRI, MEG)

- Functional topography
- Mapping hypometabolic (PET) or hypoperfused (SPECT) brain regions with the epileptogenic zone
- Functional mapping of the eloquent regions

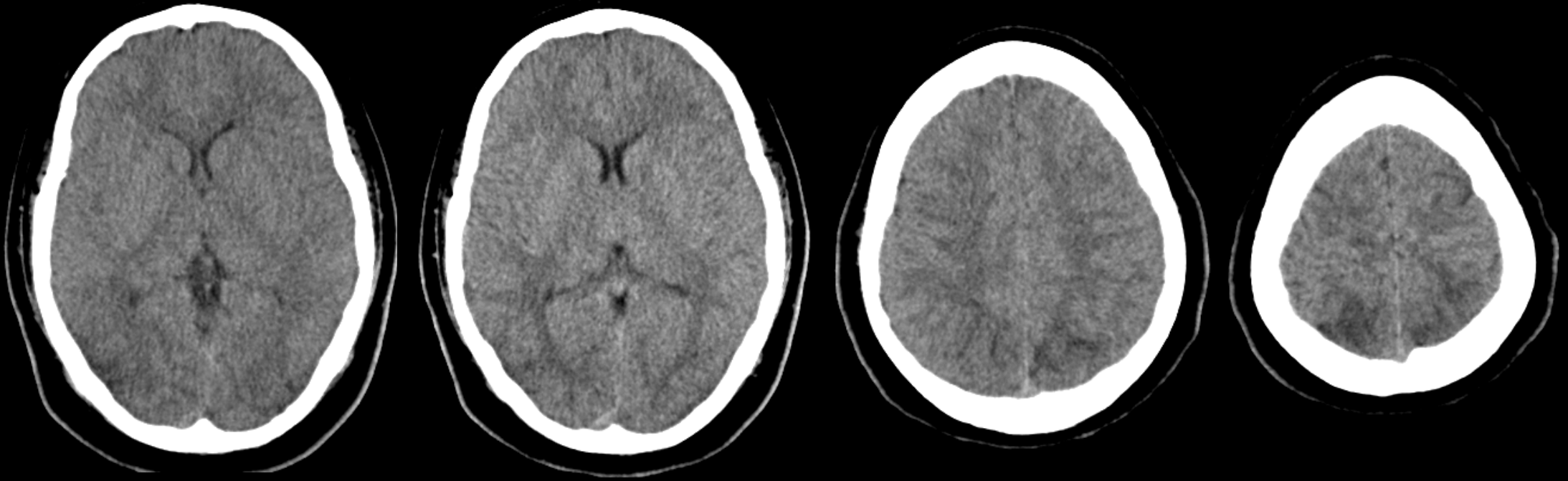
WADA TEST

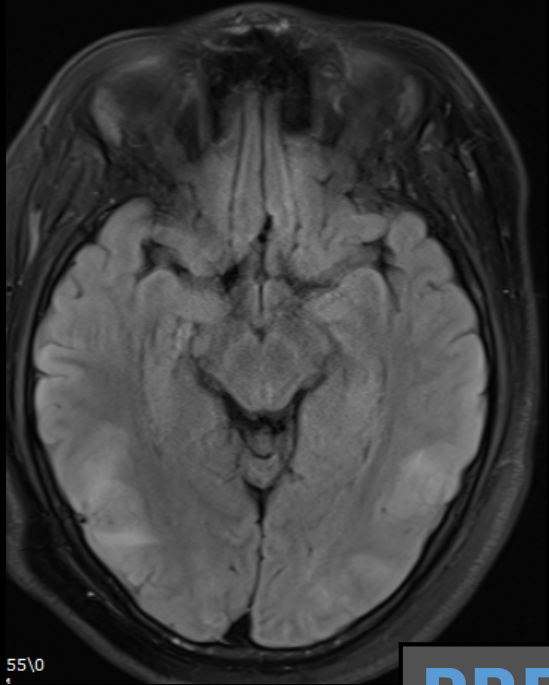
- Functional mapping
- Lateralize memory and language functions to predict side of or lobe of seizure
- Predict feasibility of surgical resection and postoperative loss of memory function

INDICATION OF CT SCAN

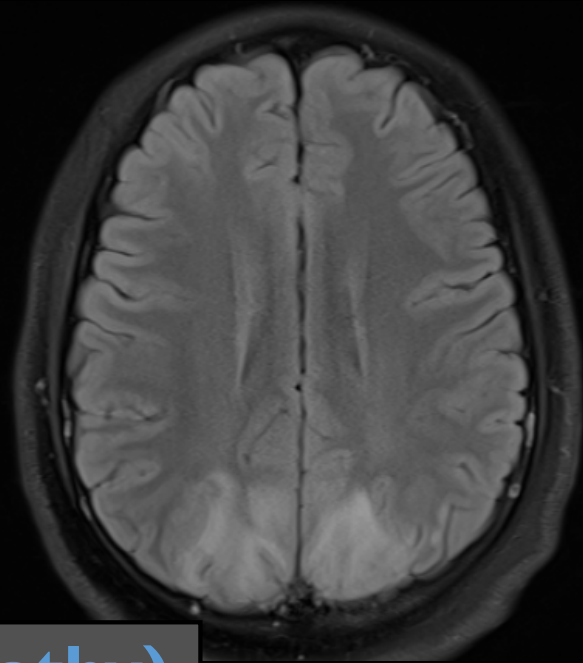
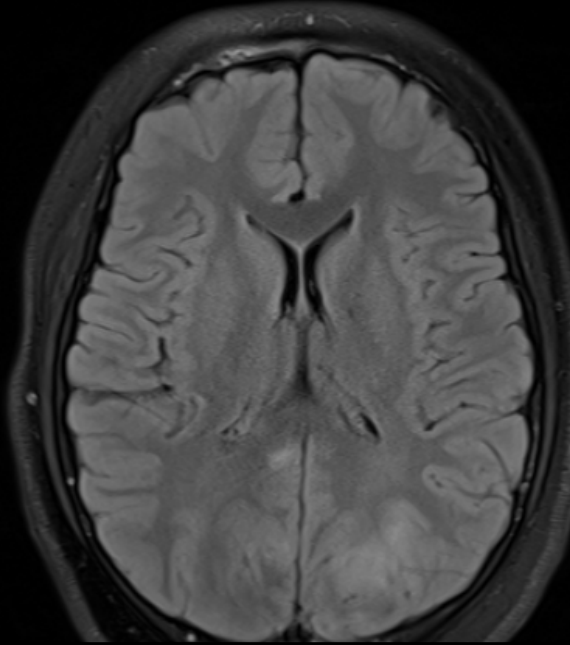
- Emergency setting
- New-onset seizure patients with symptoms (i.e. focal deficits, altered mental status, fever, trauma, persistent headache, history of cancer, anticoagulation, ventriculoperitoneal shunts, acquired immunodeficiency syndrome)
- New-onset seizures in elderly (acute stroke and tumors)

A 14-year-old boy with acute glomerulonephritis, HT and seizure
(posterior reversible encephalopathy syndrome, PRES)

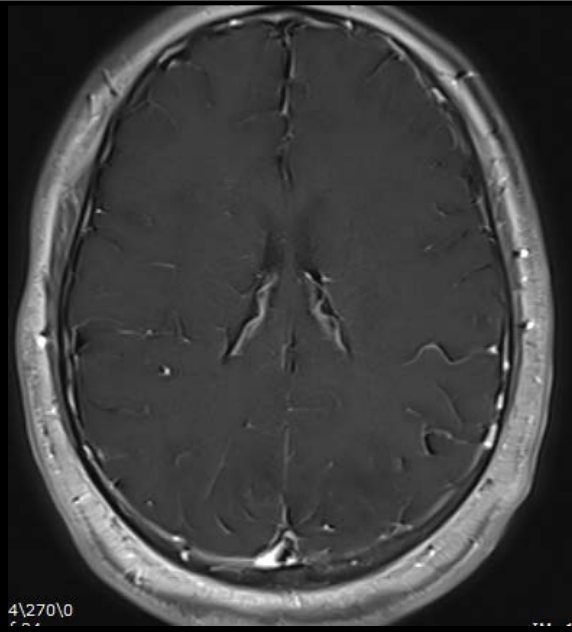
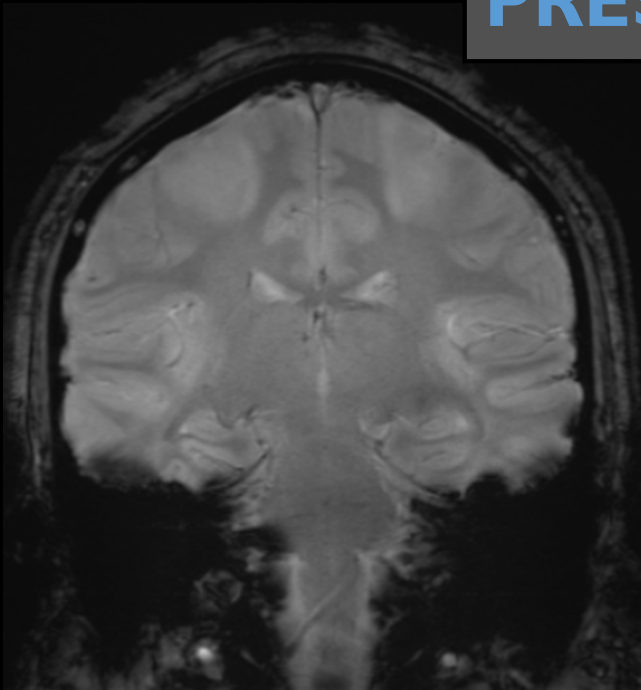




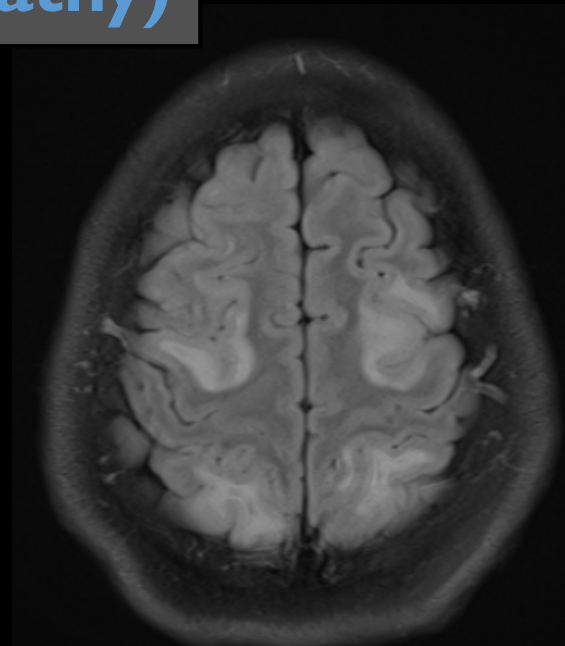
55\0



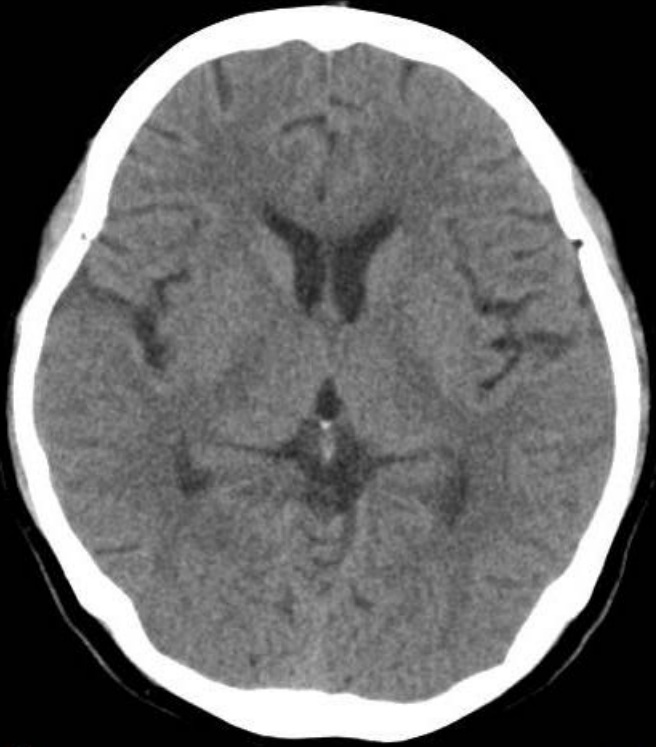PRES (HT encephalopathy)



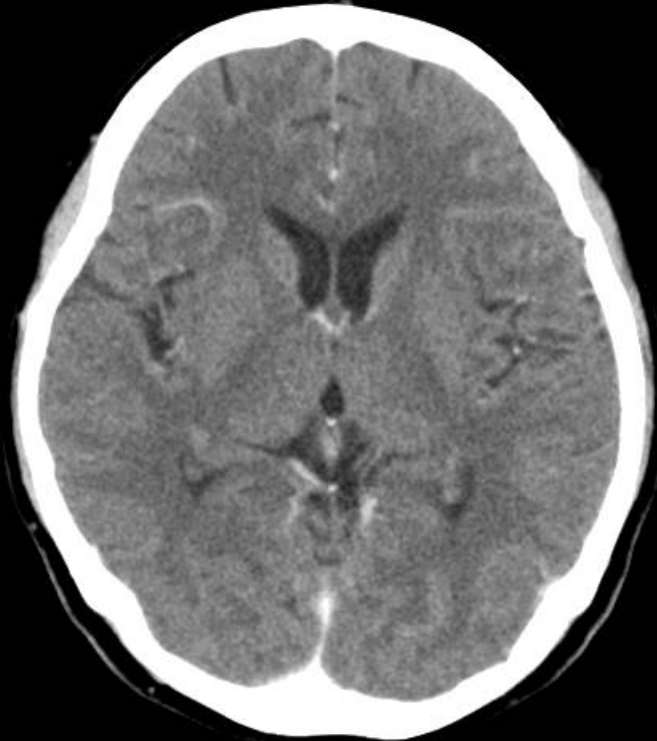4\270\0



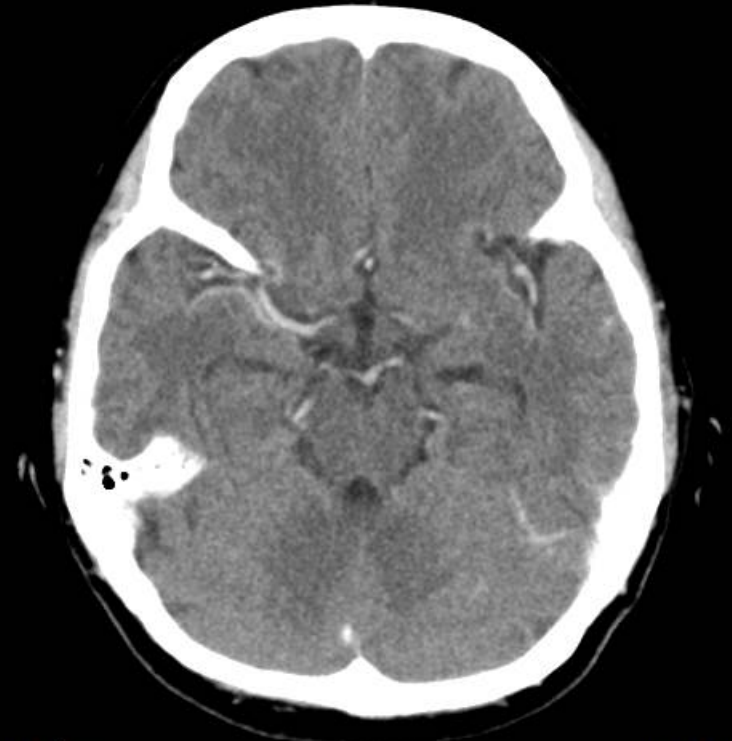A 58-year-old woman with progressive headache, diplopia, seizure and stiffness of neck.



21 of 37



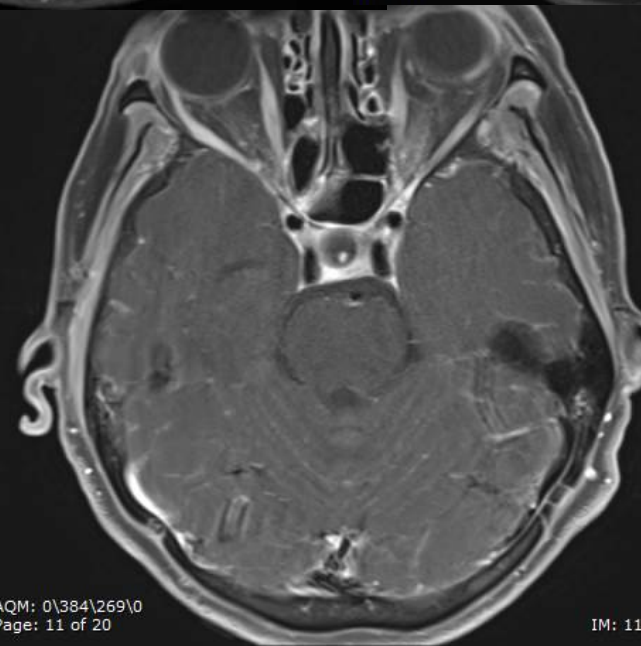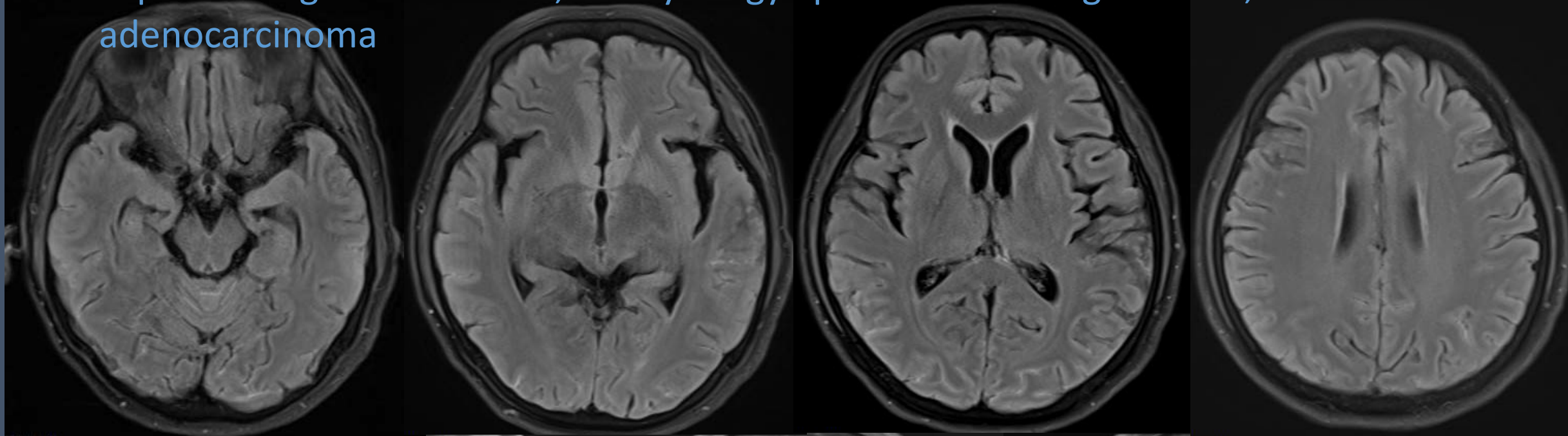
IM: 21 SE: 3 21 of 37



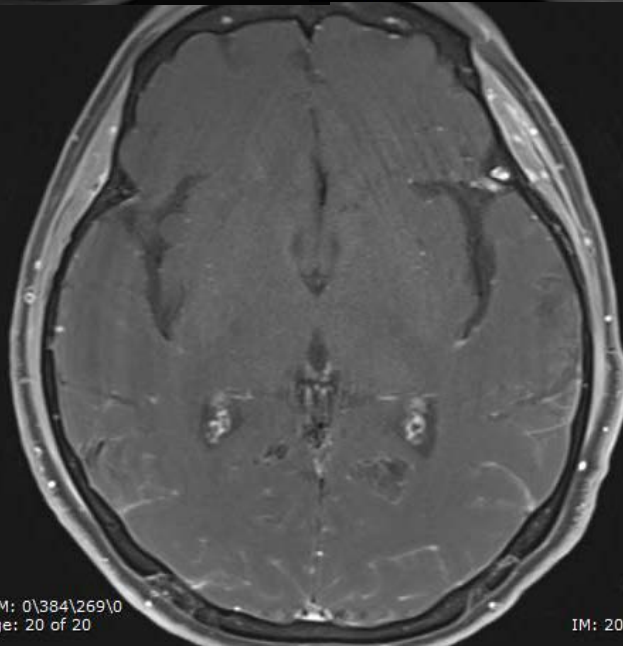
IM: 21 SE: 6 : 17 of 37

IM: 17 SE: 6

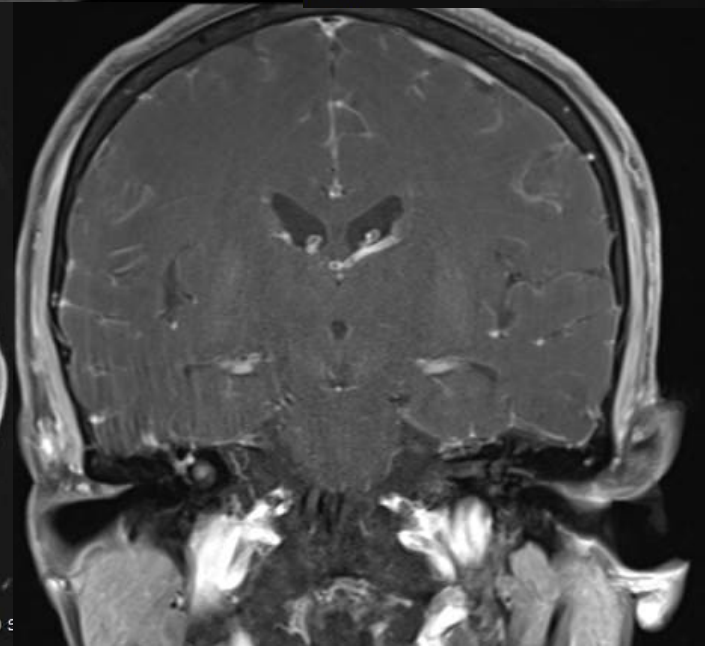
Leptomeningeal metastasis, CSF cytology : positive for malignant cell, favor metastatic adenocarcinoma



AQM: 0\384\269\0
Page: 11 of 20



M: 0\384\269\0
IM: 11je: 20 of 20



IM: 20 s

INDICATION OF MRI BRAIN

- Partial seizure, at any age
- Generalized or unclassified seizures in the first year of life or in adulthood
- Fixed deficit on neurological examination
- Difficulty obtaining seizure control with first-line AEDs
- Loss of seizure control or a change in the pattern of seizures

THE GOALS OF NEUROIMAGING IN PRESURGICAL EVALUATION

- To identify structural, and if possible, functional abnormalities
- To aid in formulating a syndromic or etiologic diagnosis
- To detect additional abnormalities
- To depict the relationship of the abnormalities to the eloquent regions of the brain (mapping of sensorimotor, language and memory functions)

PATHOLOGIC ENTITIES

- Malformation of cortical development
- Neoplasm
- Mesial temporal/hippocampal sclerosis
- Vascular abnormalities
- Gliosis and miscellaneous abnormalities

TABLE 2: Cause of Epilepsy Categorized by Age at Onset of Seizures

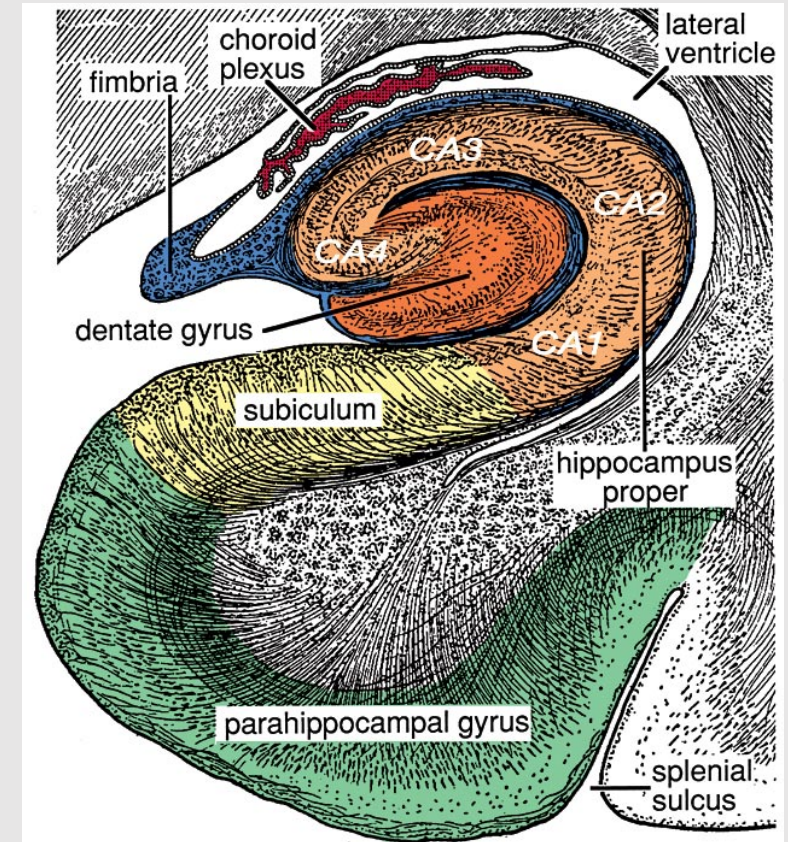
Cause	Age (yr)				
	0-2	3-20	21-40	41-60	>60
Anoxia	Yes				
Metabolic abnormalities or in-born error of metabolism	Yes				
Congenital or developmental malformations	Yes	Yes			
Infection	Yes	Yes			
Phakomatosis	Yes	Yes			
Primary generalized seizures		Yes			
Hippocampal sclerosis		Yes			
Trauma	Yes	Yes	Yes	Yes	
Vascular malformation			Yes		
Tumor			Yes	Yes	Yes
Cerebrovascular accident				Yes	Yes

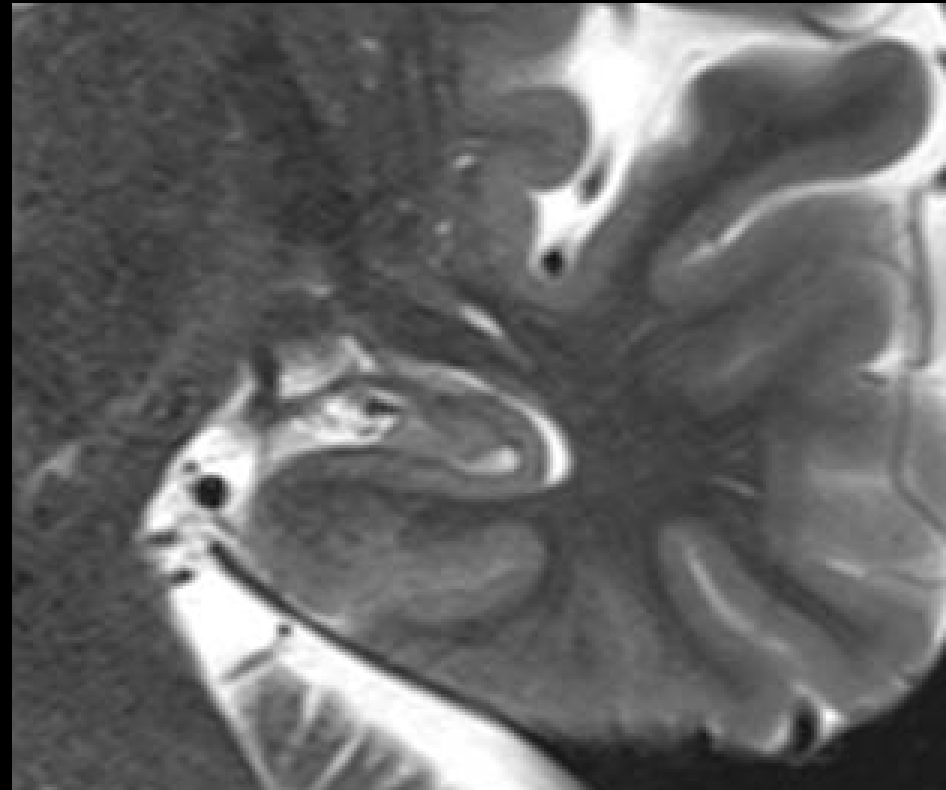
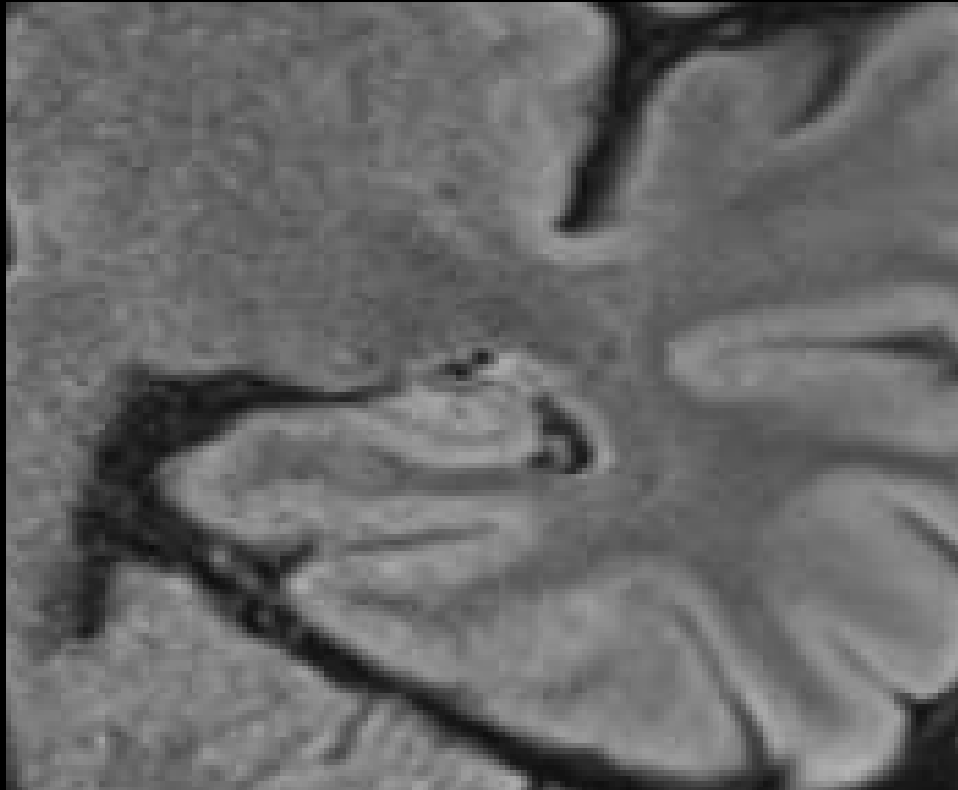
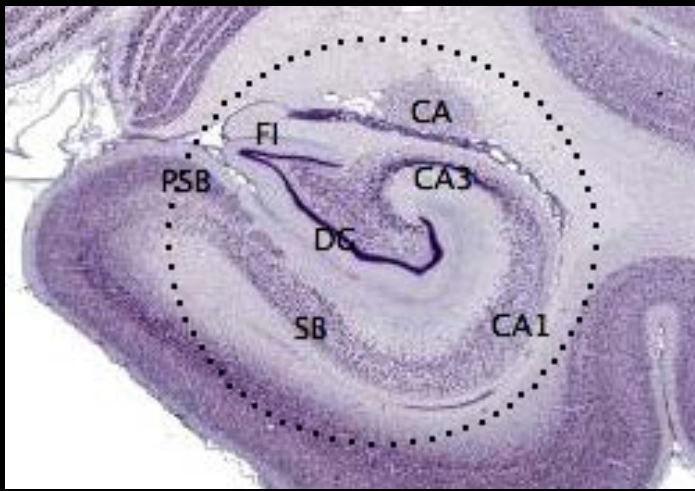
Note.—Phakomatoses include tuberous sclerosis, Sturge-Weber syndrome, and neurofibromatosis.

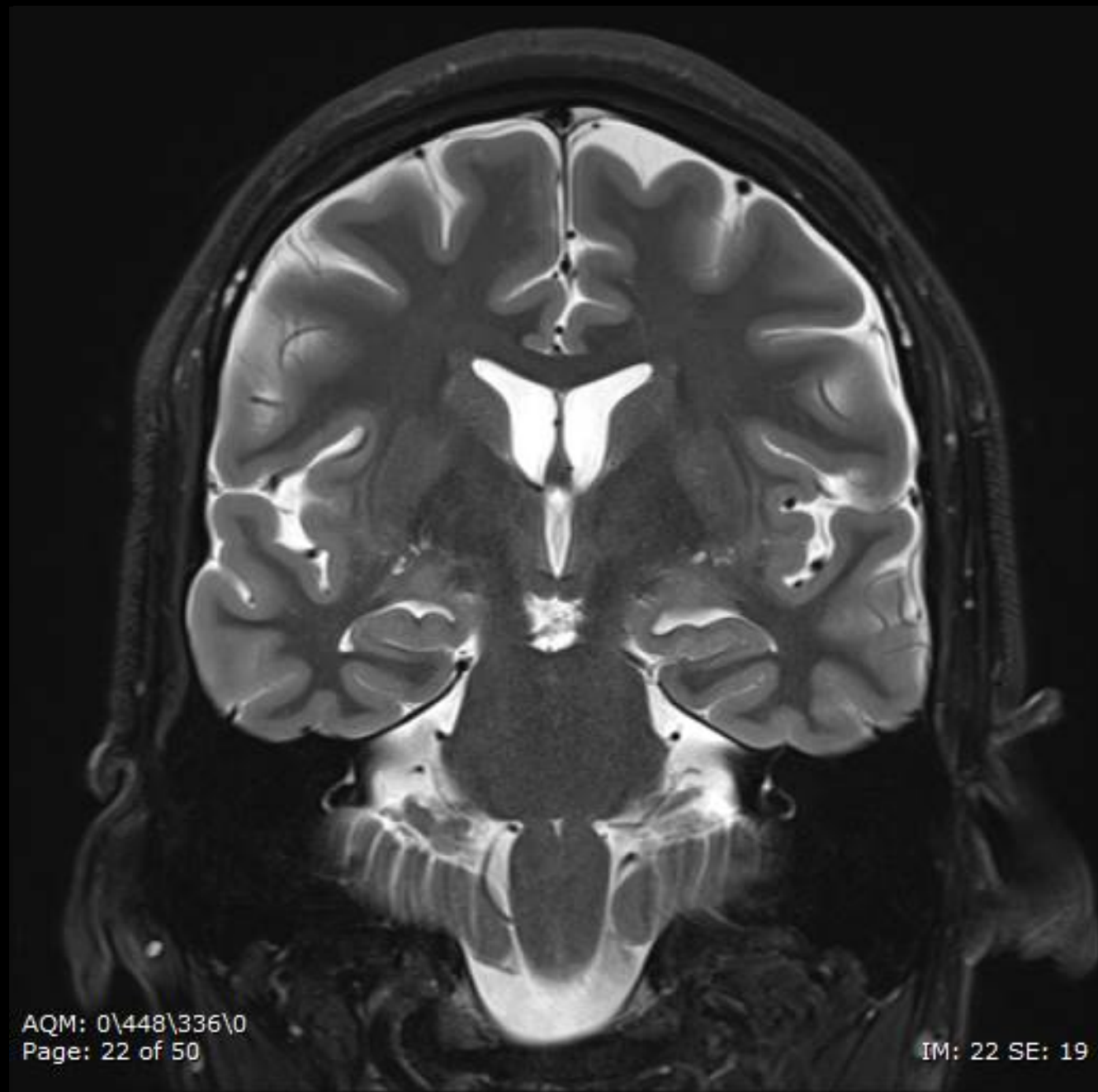
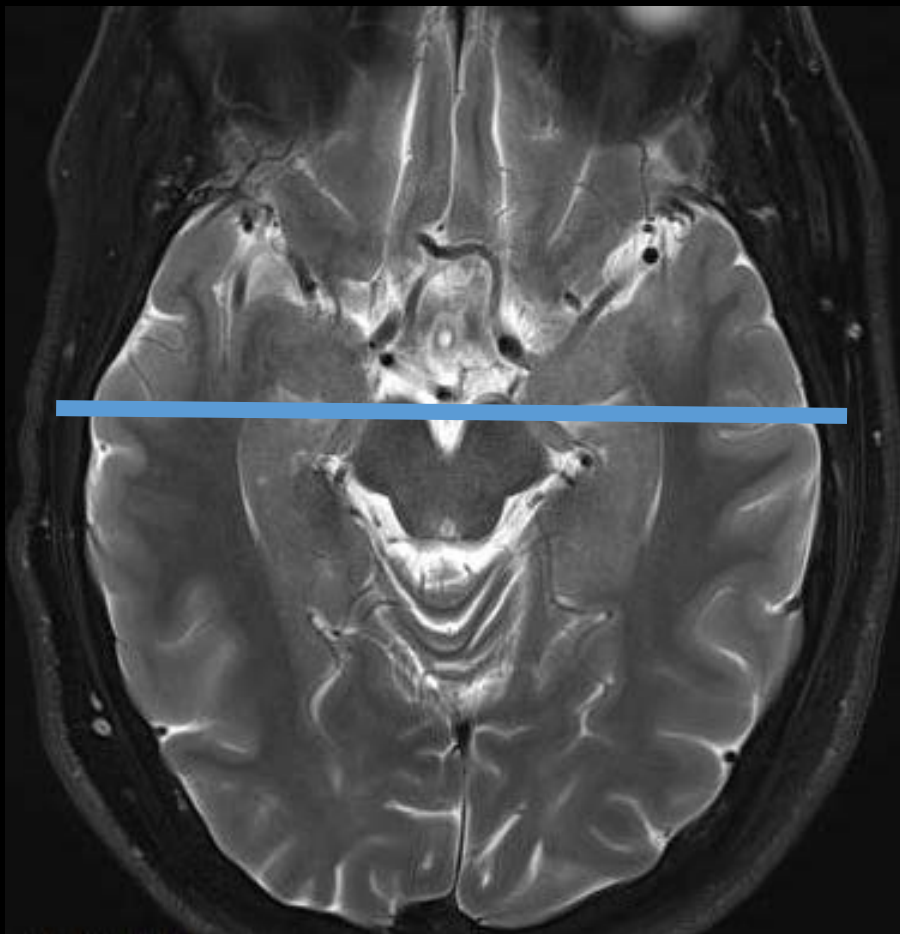
HIPPOCAMPAL SCLEROSIS

Hippocampus

- curved structure on the medial aspect of the temporal lobe
- consisting of complex U-shaped layers of the dentate gyrus and cornu amonis, interlocked together
- cornu amonis : CA 1 through CA 4
- cornu amonis → subiculum → parahippocampal gyrus

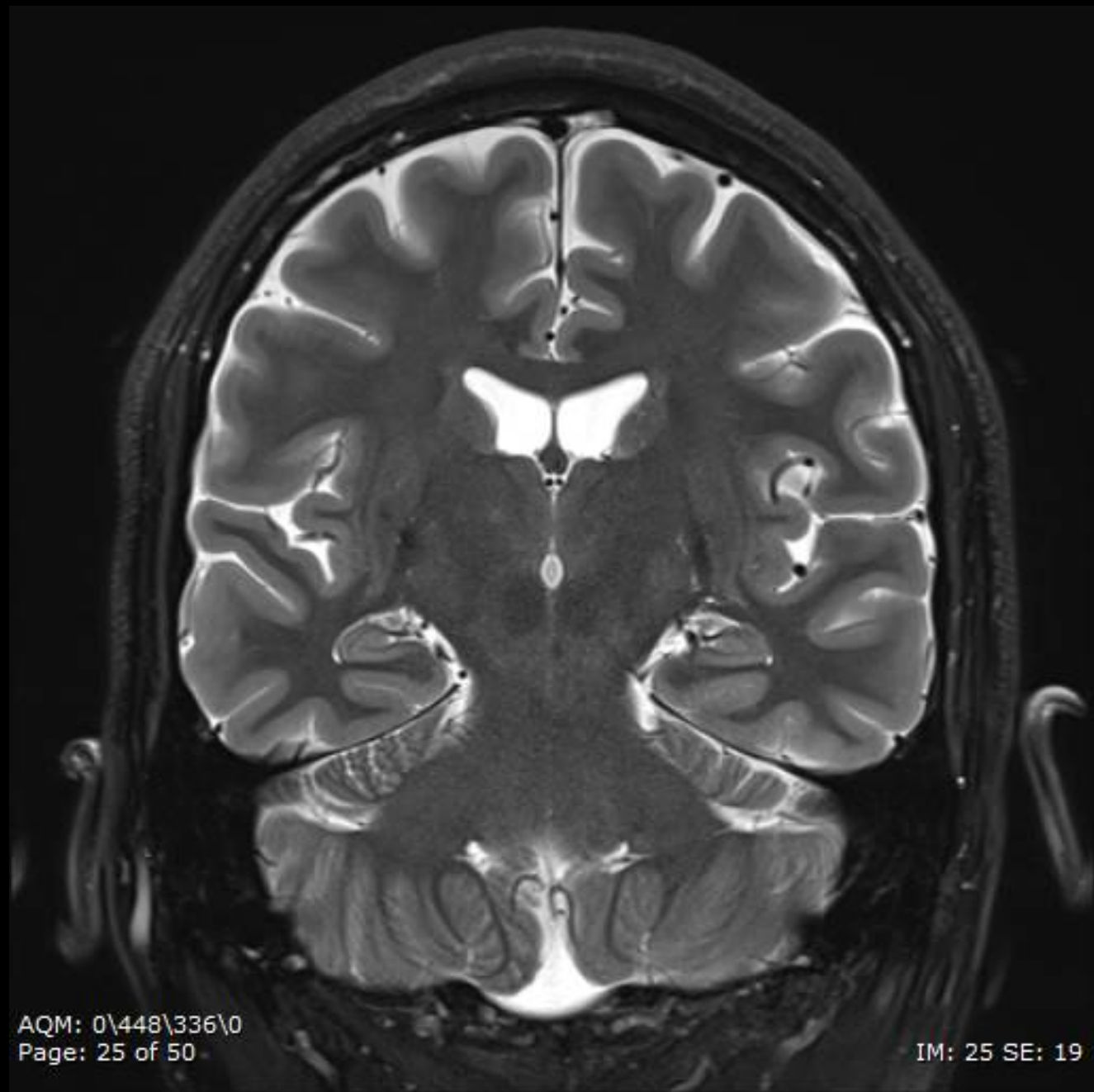
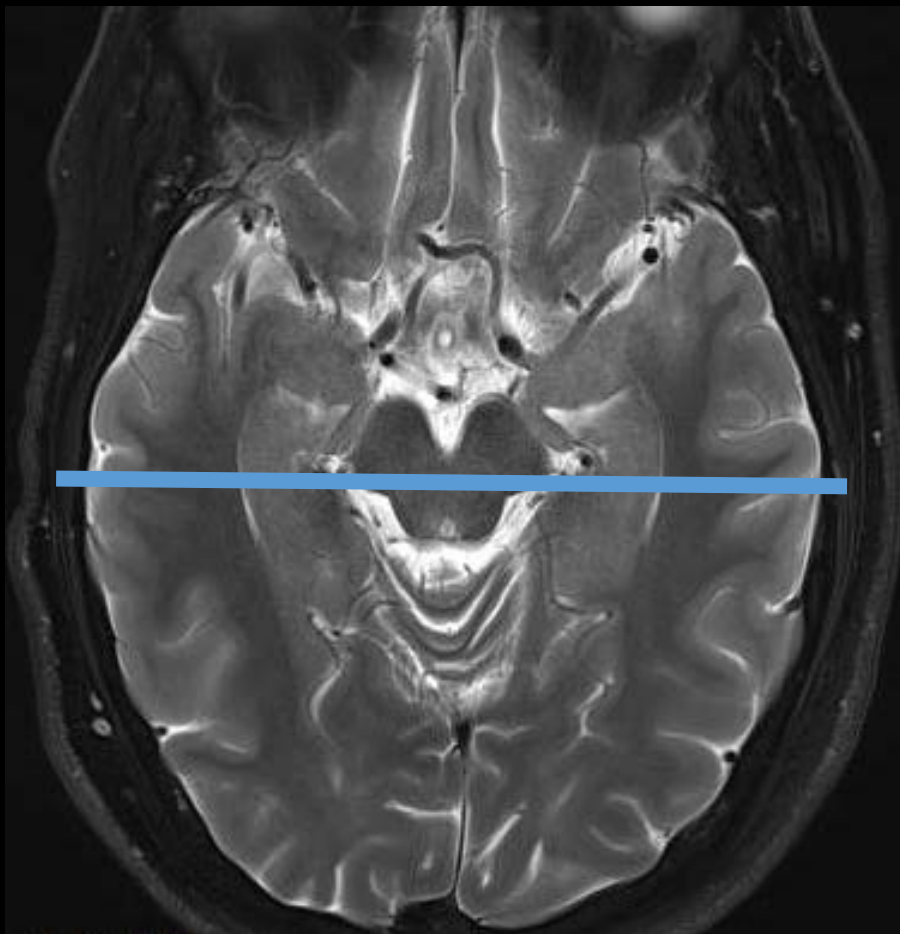


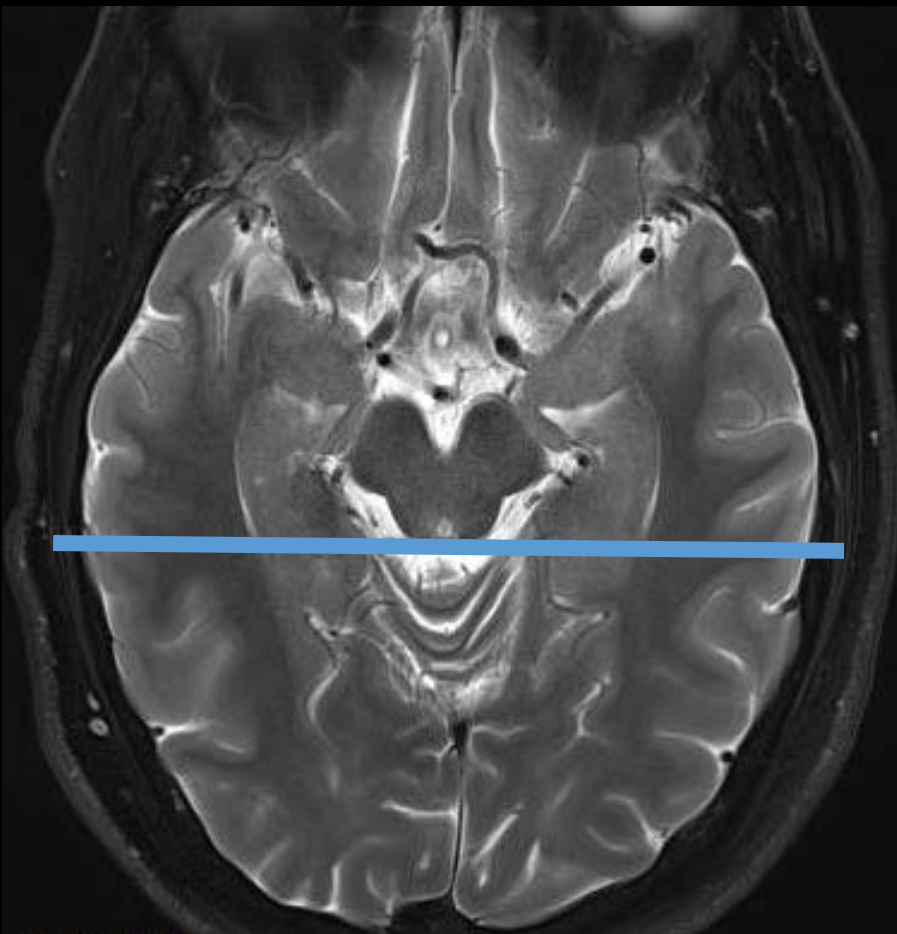




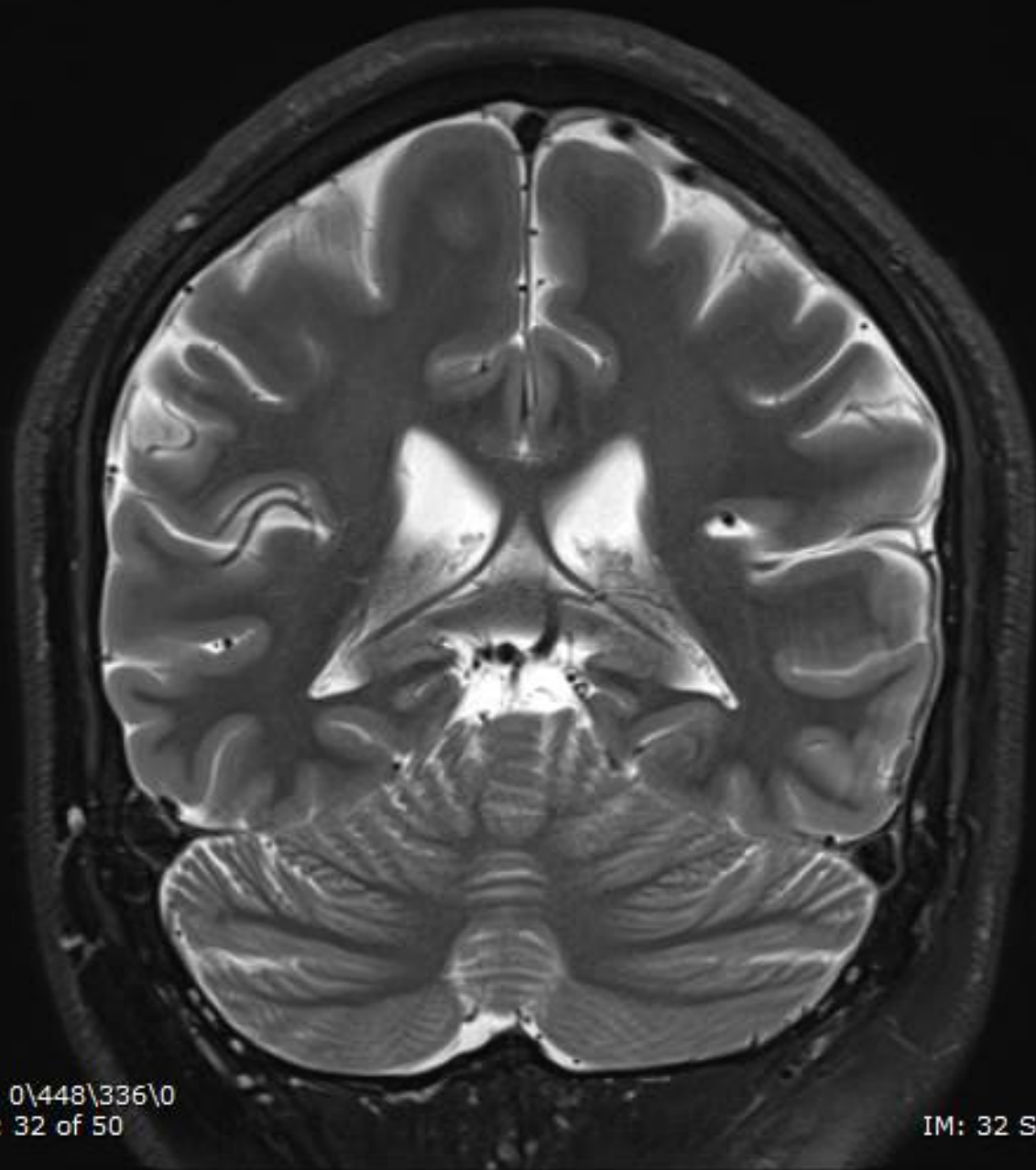
AQM: 0\448\336\0
Page: 22 of 50

IM: 22 SE: 19





AQM: 0\448\336\0
Page: 32 of 50

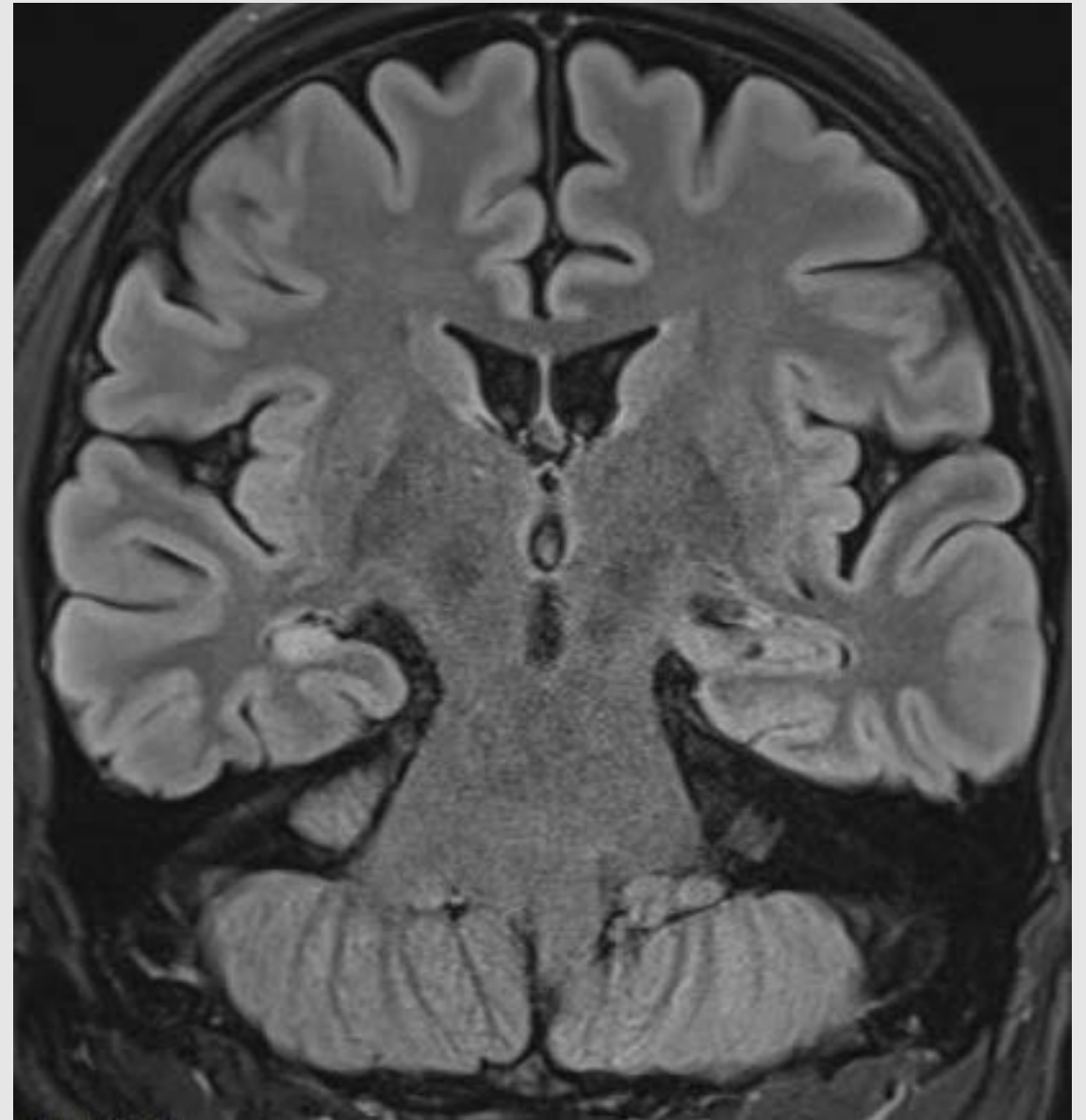


IM: 32 SE: 19

MR FEATURES OF HIPPOCAMPAL SCLEROSIS

Principle hippocampal findings

- Hippocampal atrophy
- Signal alterations (hyperintense on T2WI and FLAIR)
- Loss of internal architecture

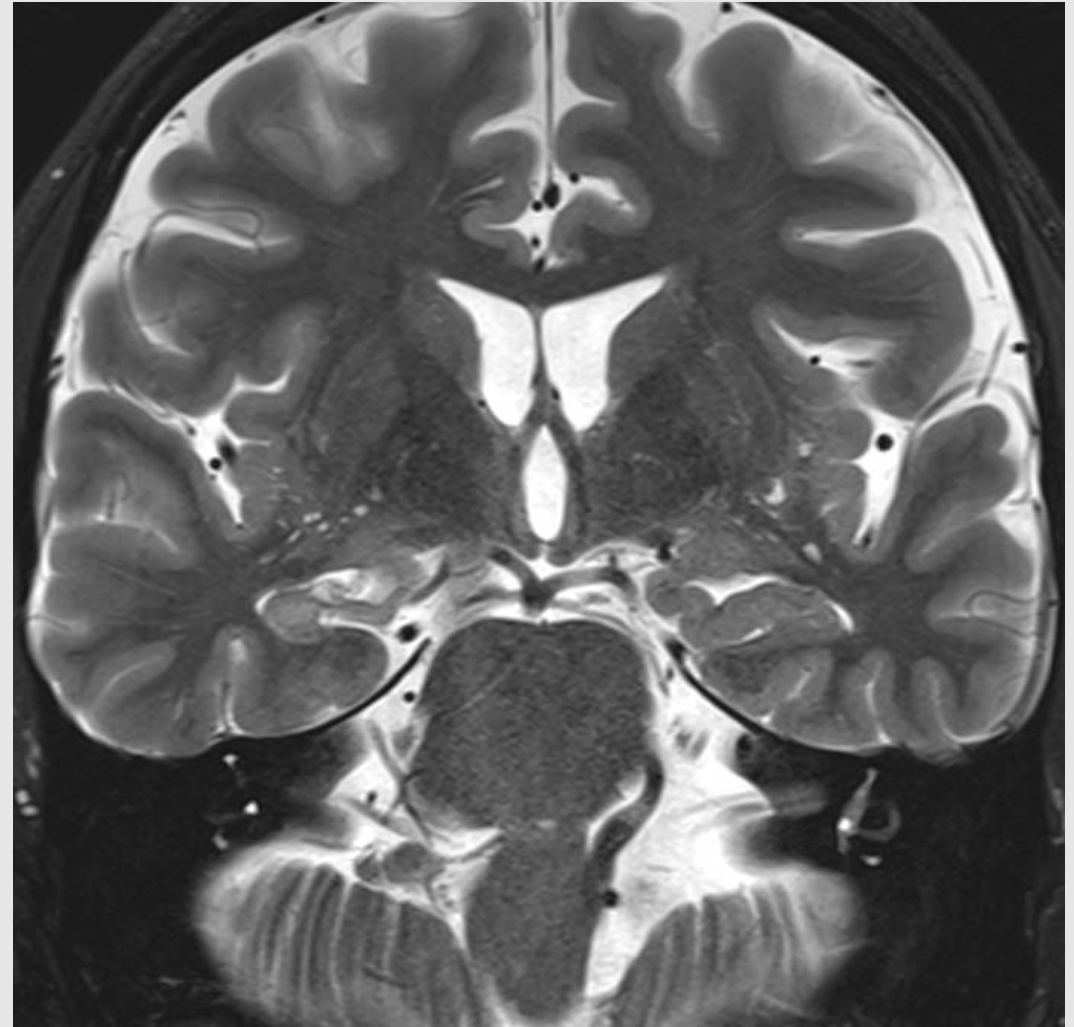


MR FEATURES OF HIPPOCAMPAL SCLEROSIS

Secondary findings

Temporal lobe

- Ipsilateral loss of hippocampal head digitations
- Dilation of temporal horn
- Temporal lobe atrophy
- Collateral WM atrophy
- Anterior temporal WM change

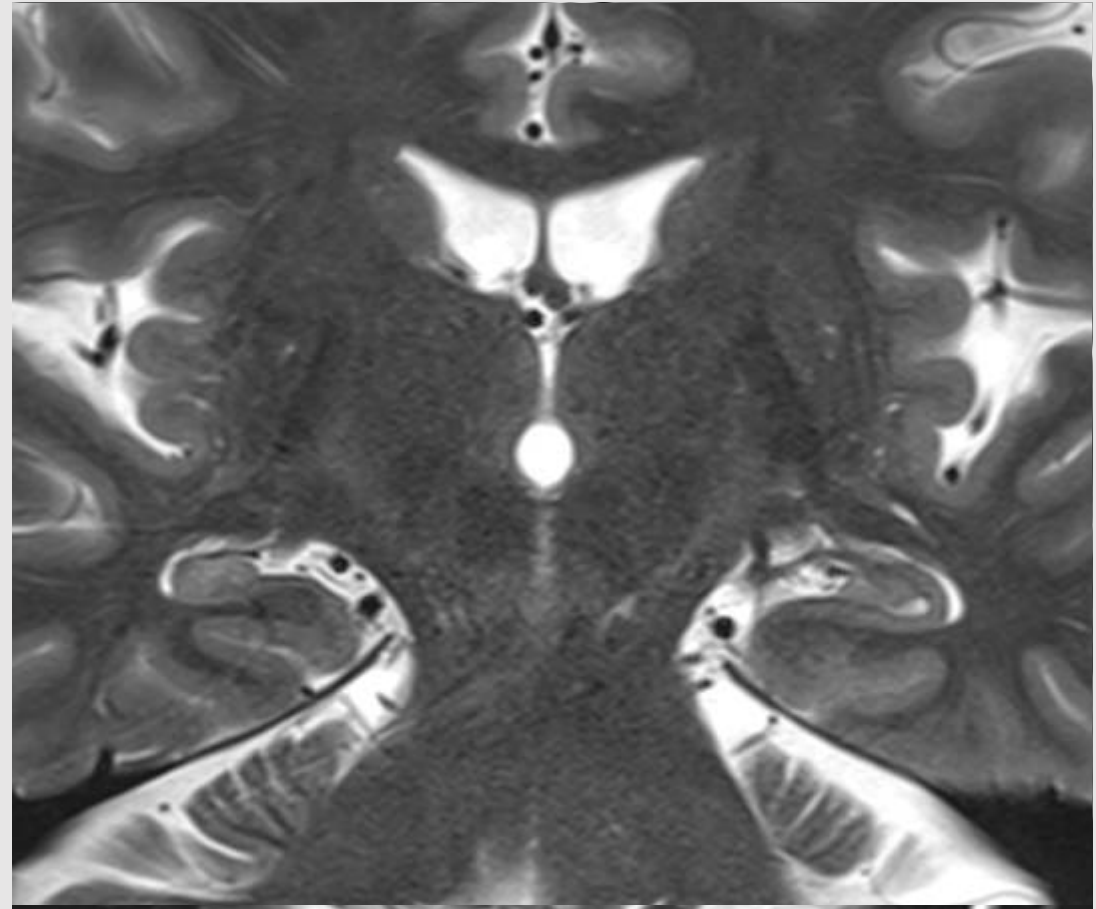


MR FEATURES OF HIPPOCAMPAL SCLEROSIS

Secondary findings

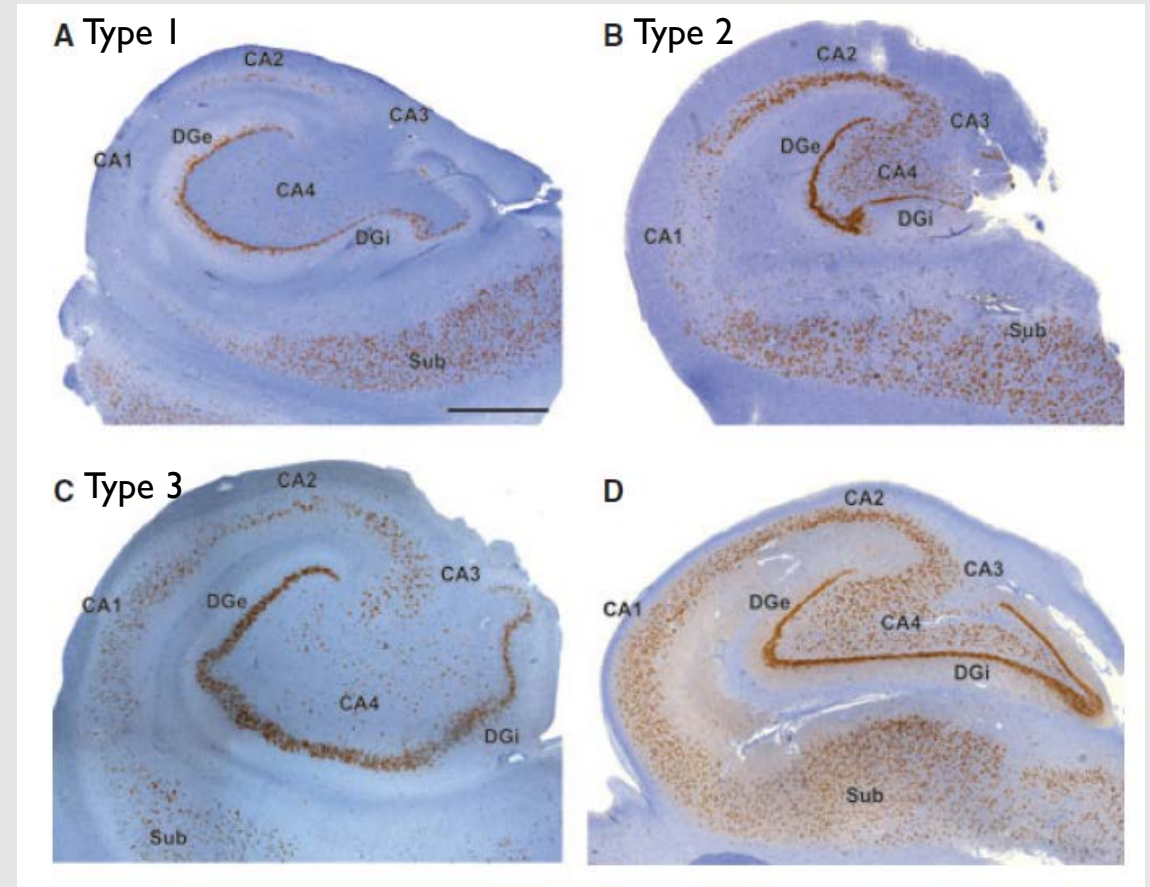
Extratemporal lobe

- Fornix atrophy
- Mammillary body atrophy
- Thalamic atrophy
- Caudate atrophy



THE ILAE CLASSIFICATION OF HS IN PATIENTS WITH TLE

- HS ILAE type 1 = severe neuronal loss and gliosis predominantly in CA1 and CA 4 regions
- HS ILAE type 2 = CA 1 predominant neuronal cell loss and gliosis
- HS ILAE type 3 = CA 4 predominant neuronal cell loss and gliosis



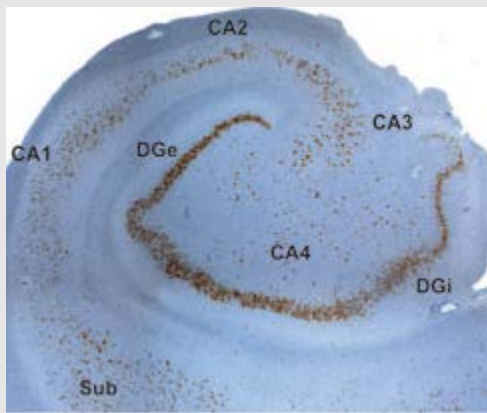
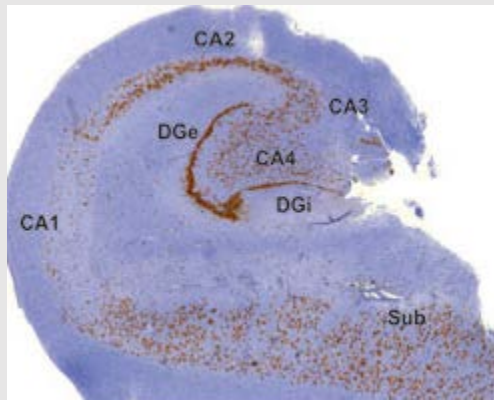
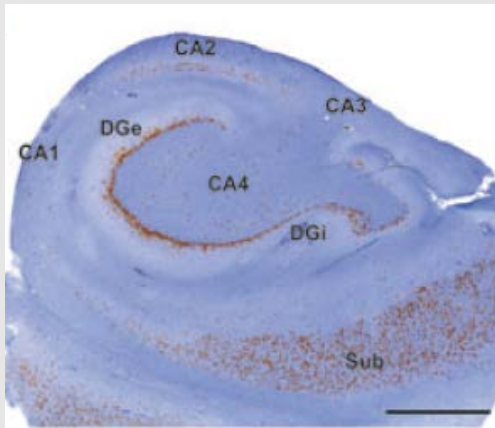
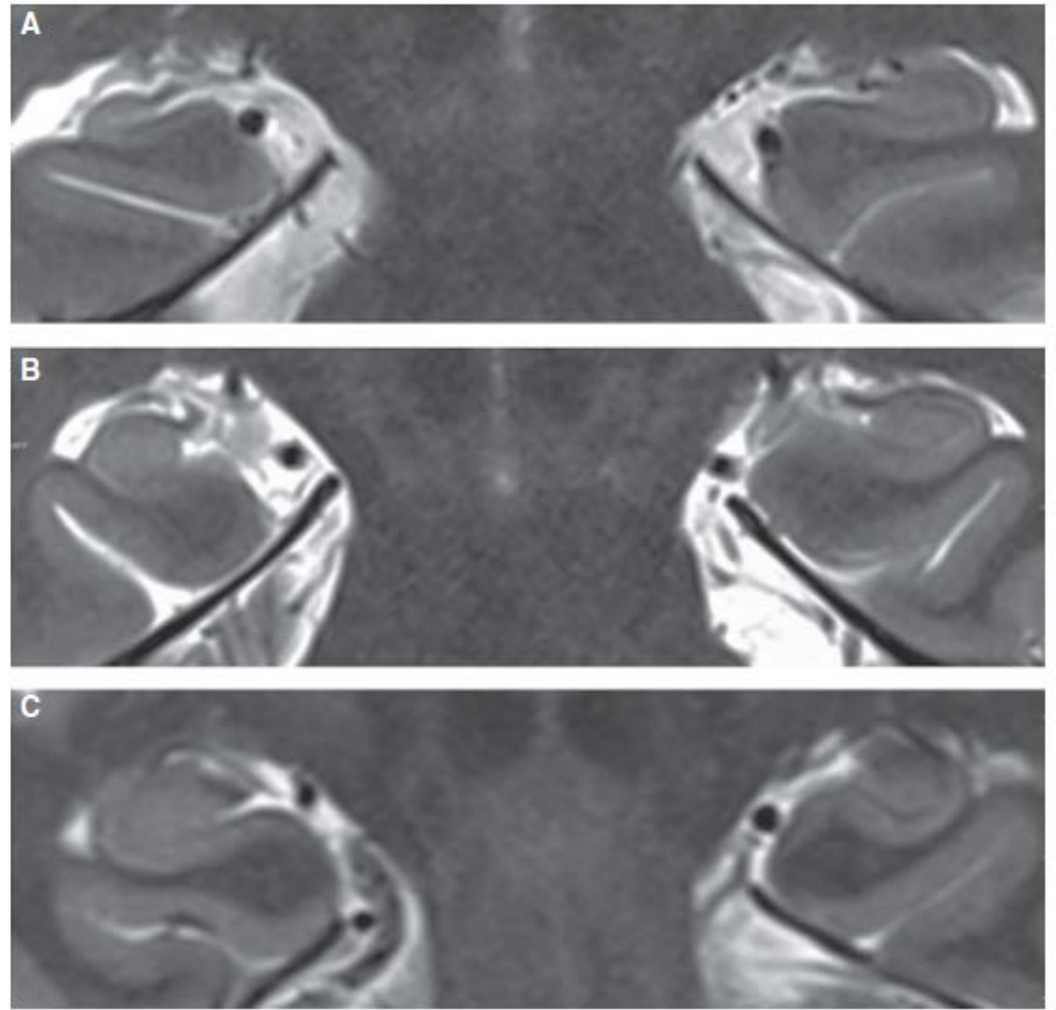
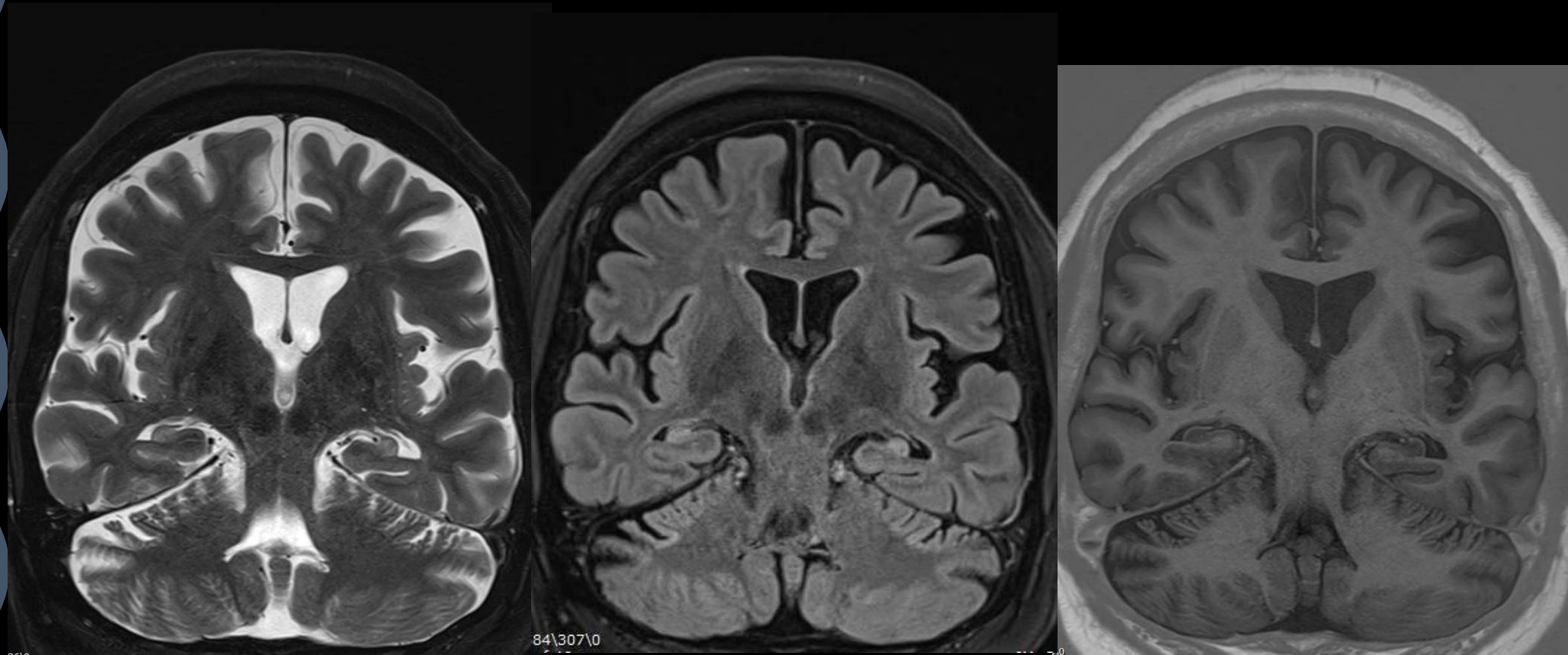


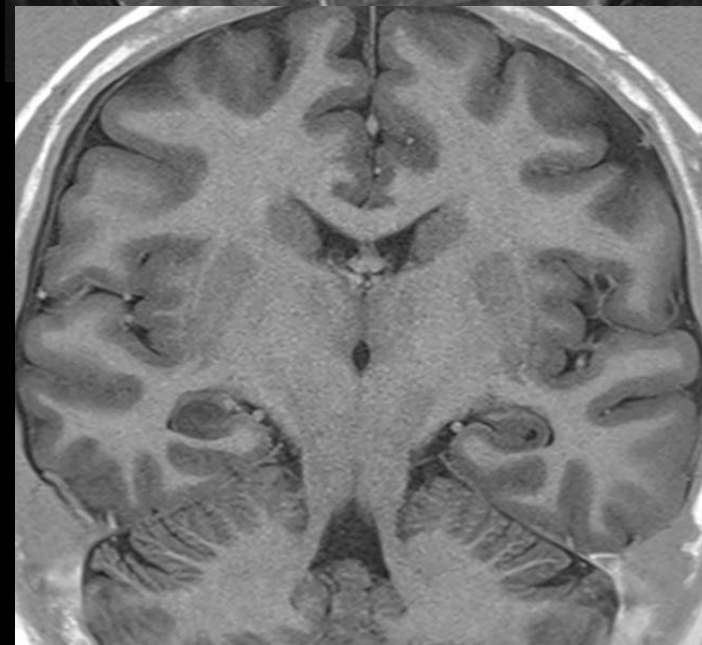
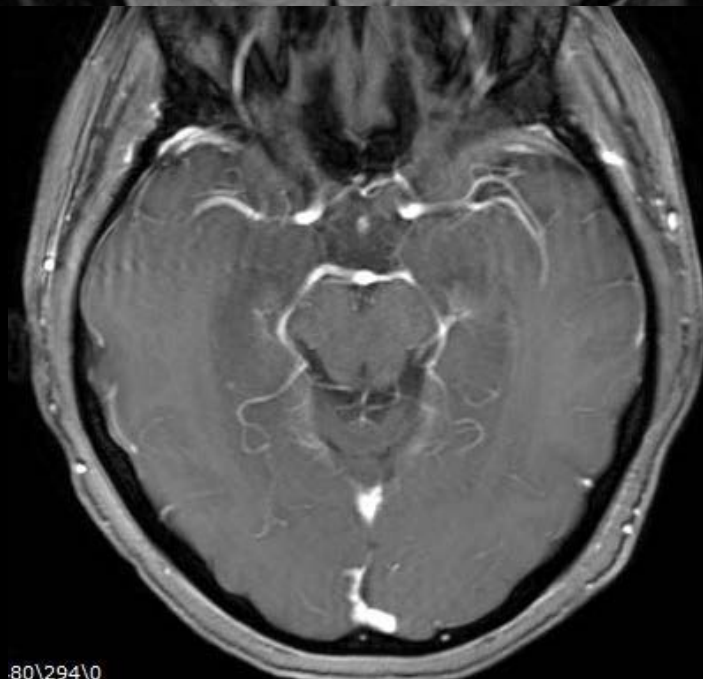
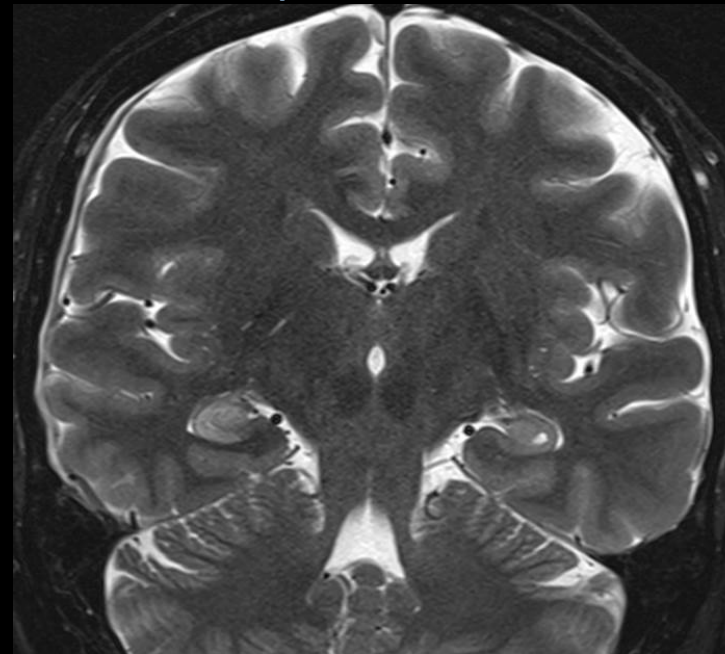
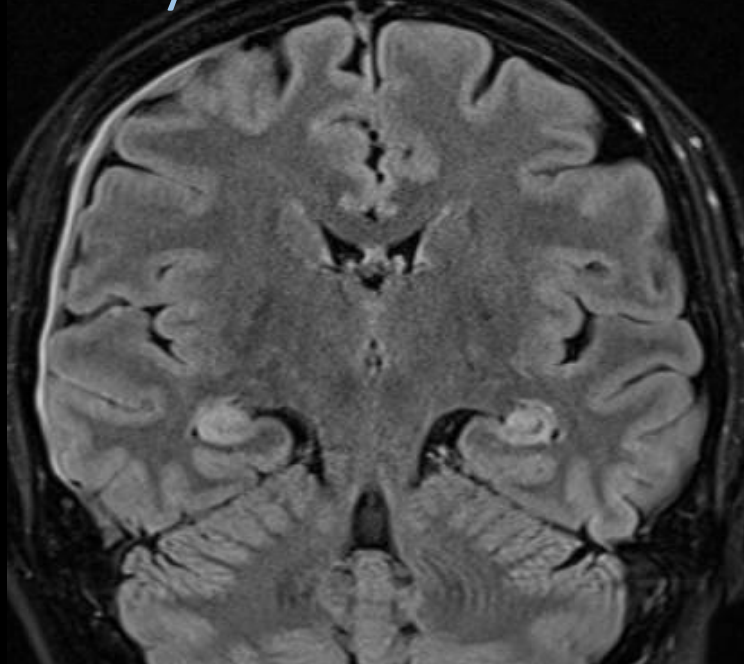
Figure 4.
 3T MRI findings in
 histopathologically verified types of
 TLE-HS. Presurgical T₂ – MRI
 findings at three Tesla in TLE
 patients with histopathologically
 classified hippocampal sclerosis on
 the right side (left on panel). (A)
 ILAE HS type 1. (B) ILAE HS type 2.
 (C) ILAE HS type 3. In these specific
 examples, volumetric loss is severe
 in ILAE HS type 1, moderate in ILAE
 HS type 2, but virtually not
 detectable in ILAE HS type 3.
Epilepsia © ILAE



A 32-year-old woman with bilateral MTS



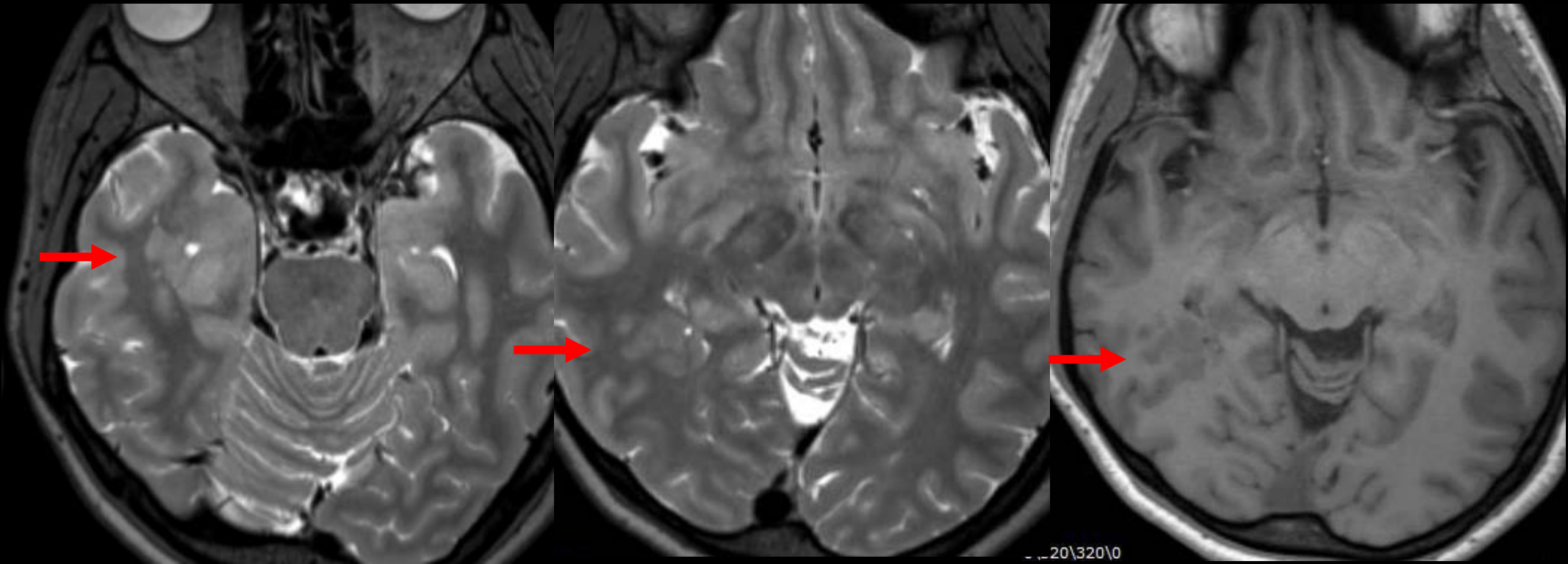
A 39-year-old woman with GABA B encephalitis and seizure



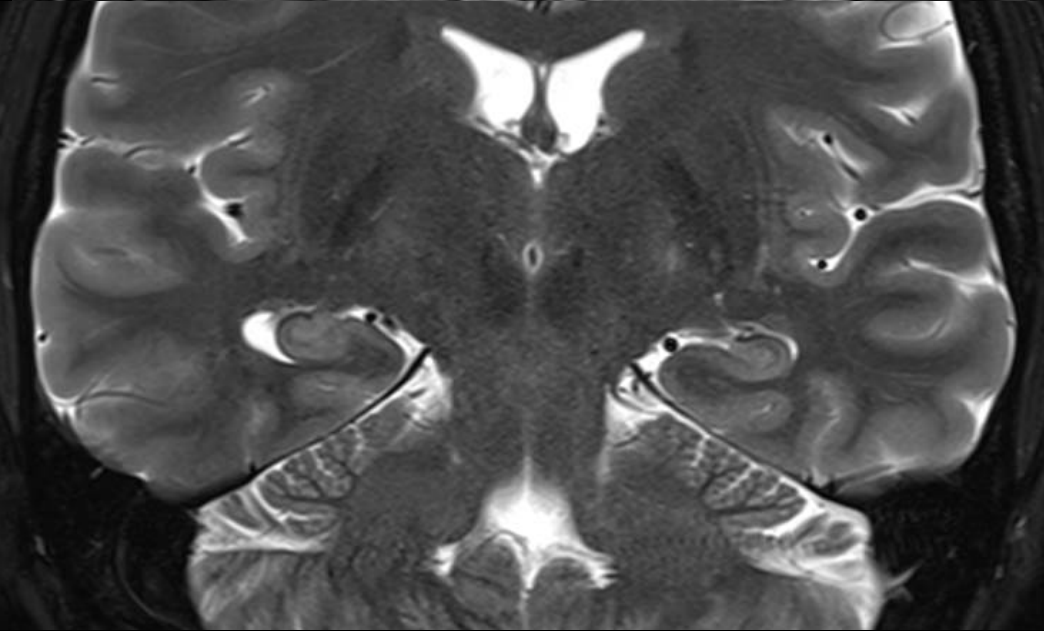
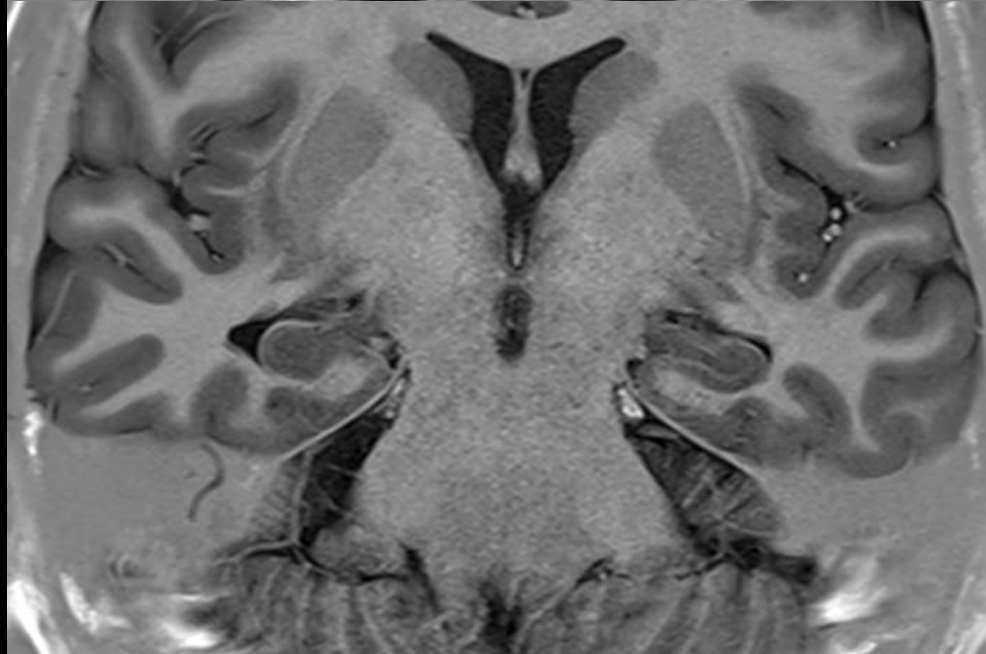
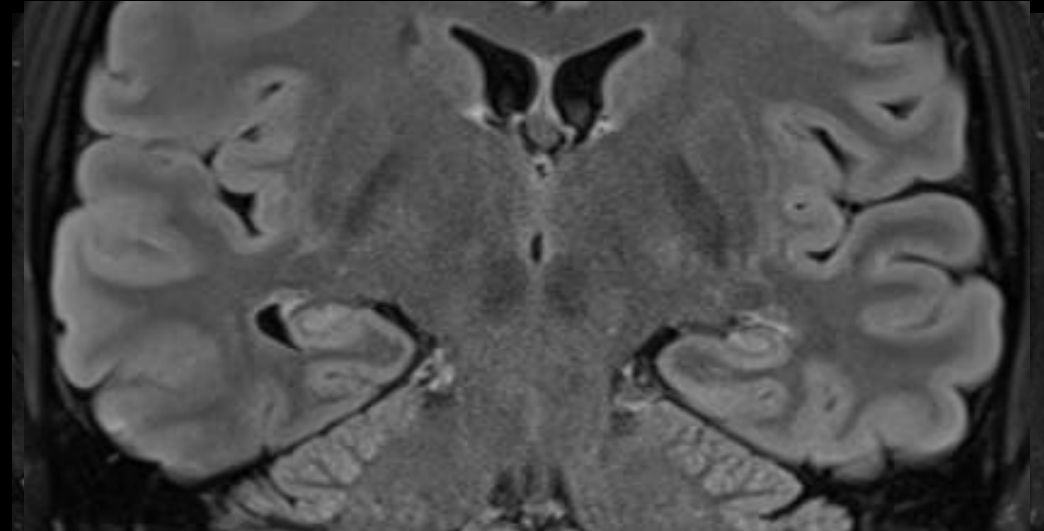
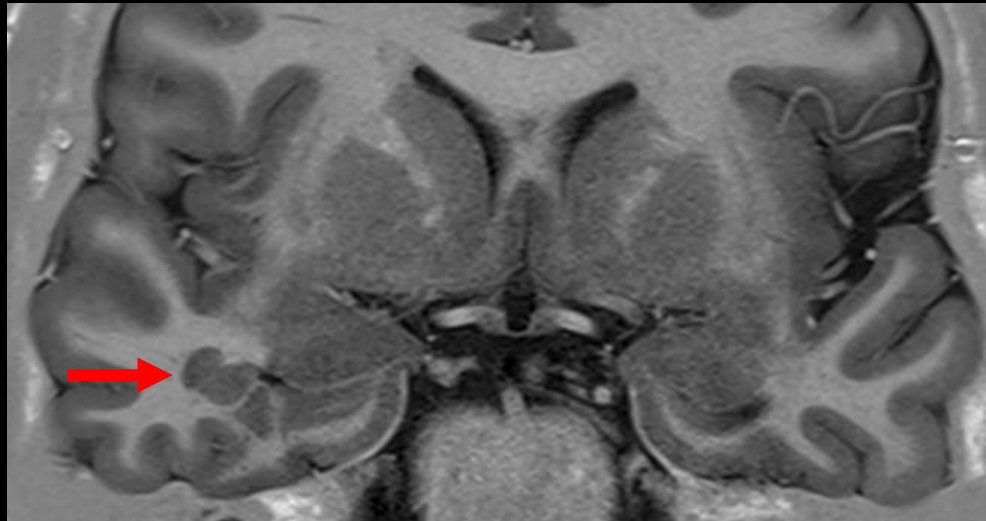
DUAL PATHOLOGY

A 36-year-old woman with focal epilepsy, onset at the age of 25

Subcortical-subependymal heterotopia at right temporal lobe and right MTS



A 36-year-old woman with focal epilepsy, onset at the age of 25
Subcortical-subependymal heterotopia at right temporal lobe and right MTS



MR FEATURES OF MALFORMATIONS OF CORTICAL DEVELOPMENT

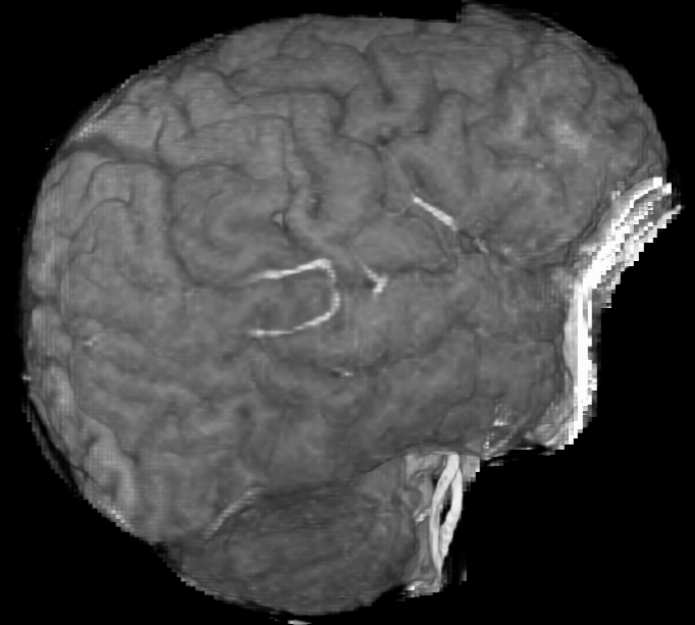
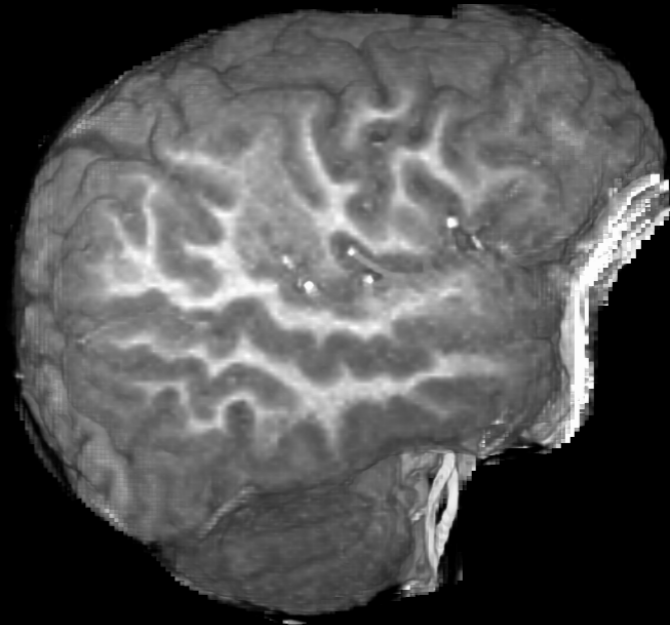
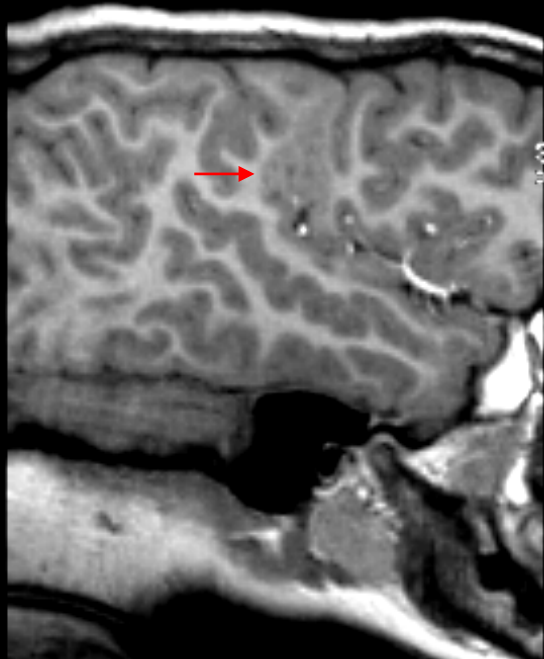
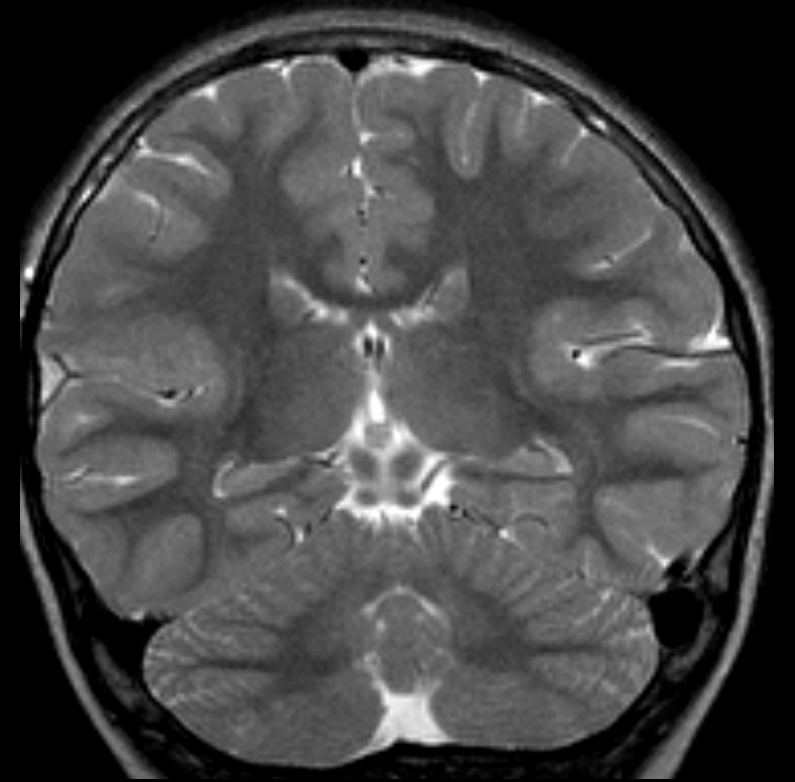
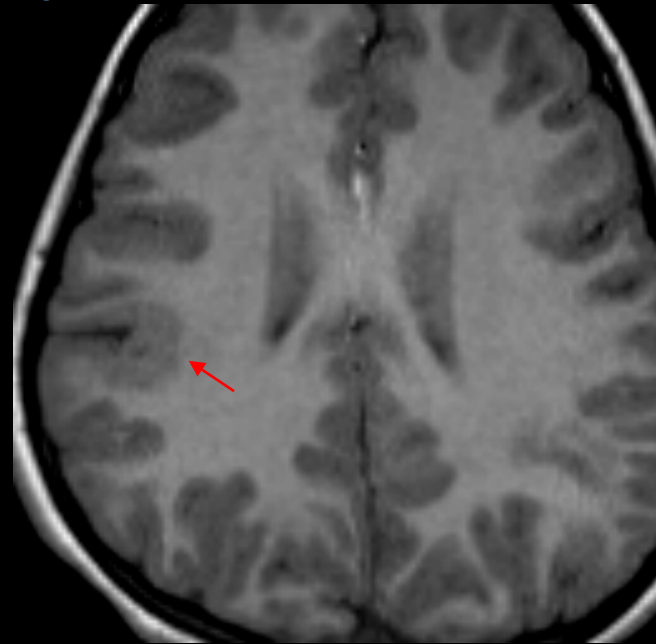
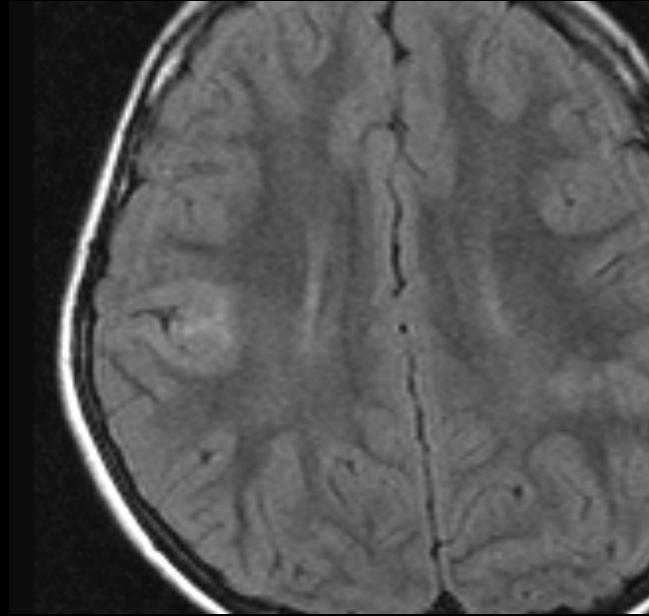
- Cortical thickening
- Blurring or indistinctness of gray-white matter junction
- Hyperintensity of gray matter
- Irregularity of gray-white matter junction
- Macrogyria
- Paucity of gyri (pachygyri)
- Polymicrogyria (multiple small gyri)
- CSF cleft and cortical dimple
- Altered sulcal morphology
- Radial bands
- Heterotopic GM, ependymal or subcortical
- Band heterotopia
- Transmantle heterotopia
- Hemispheric enlargement

FOCAL CORTICAL DYSPLASIA

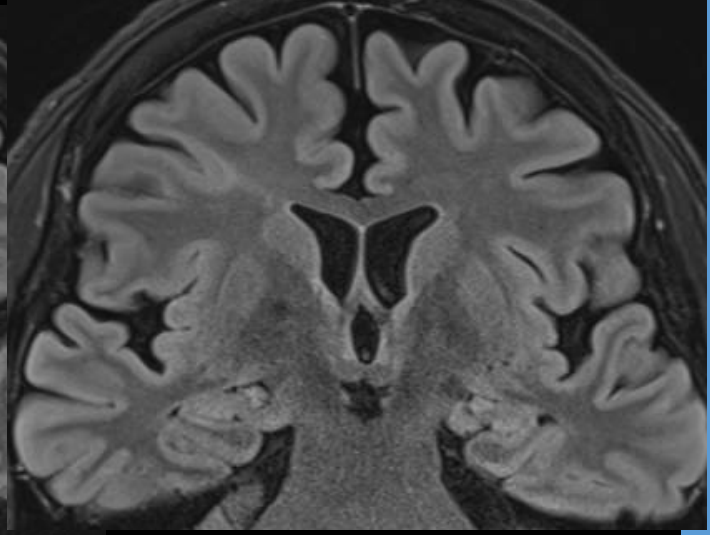
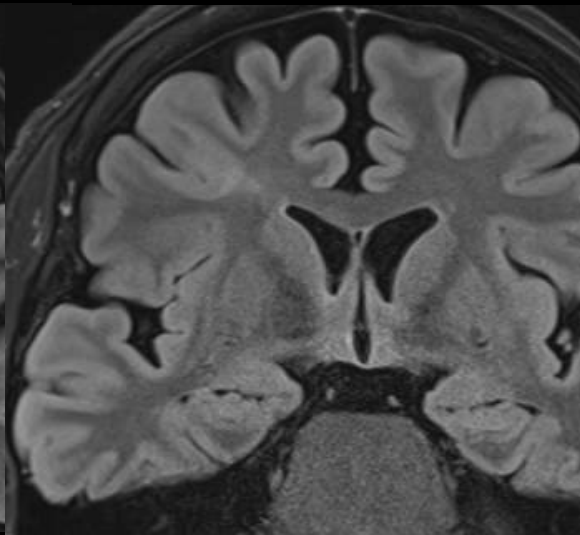
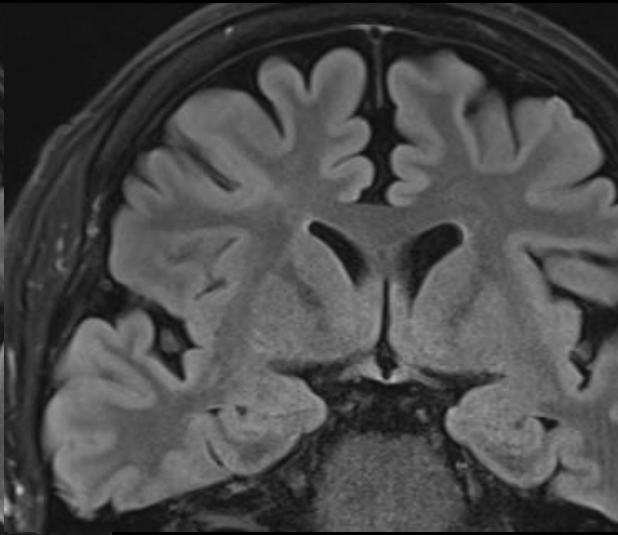
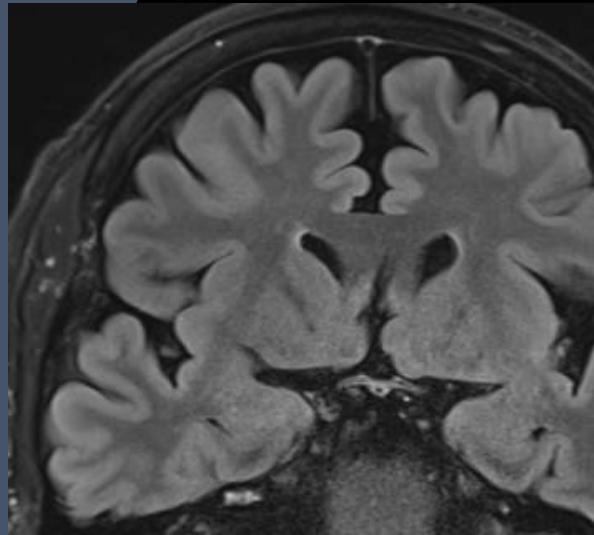
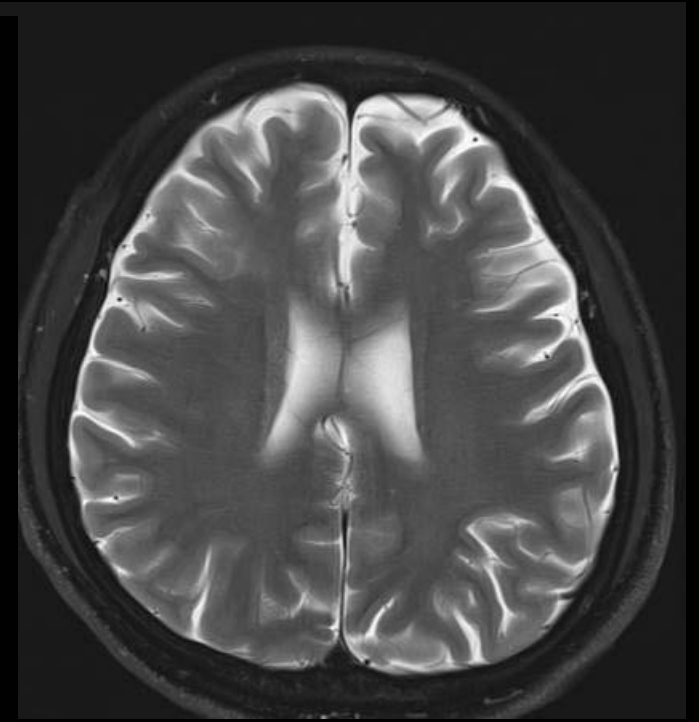
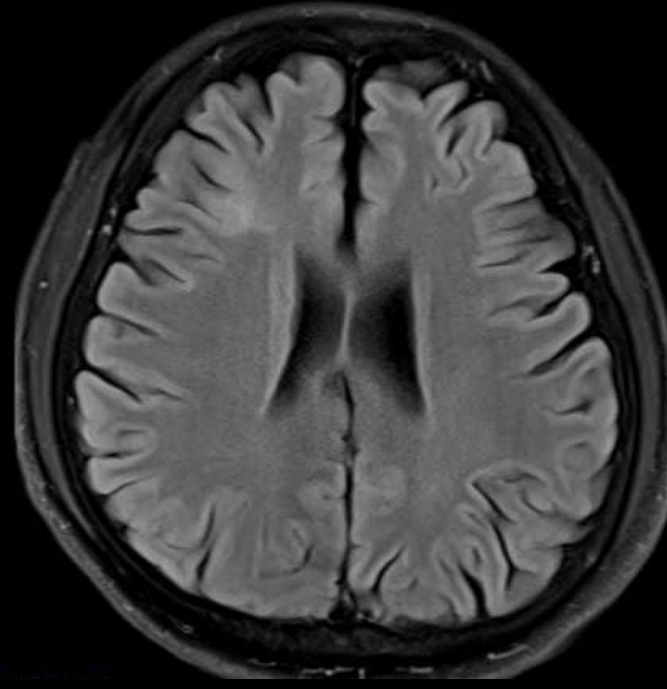
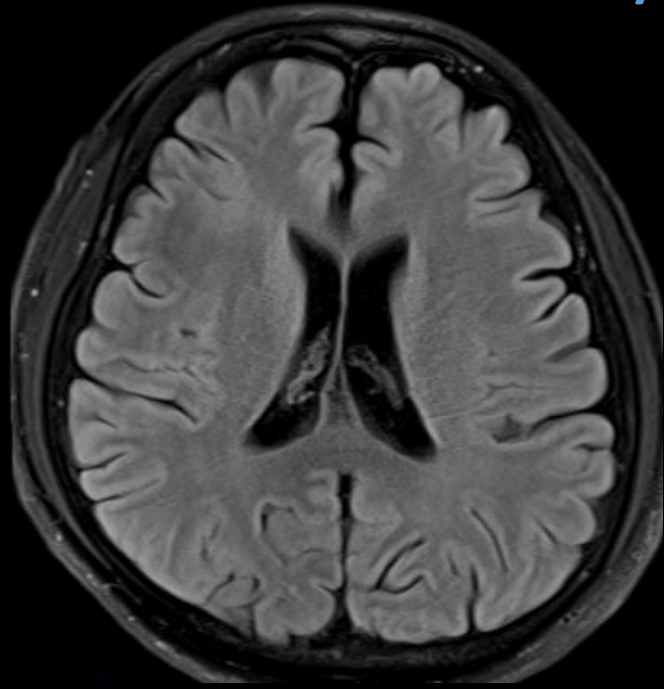
MRI findings:

- cortical thickening
- blurring of WM-GM junction with abnormal architecture of subcortical layer
- altered signal from WM with or without the penetration through cortex (transmantle sign)
- altered signal from GM
- abnormal sulcal or gyral pattern
- segmental and/or lobar hypoplasia/atrophy

Focal Cortical Dysplasia



Focal Cortical Dysplasia



FOCAL CORTICAL DYSPLASIA

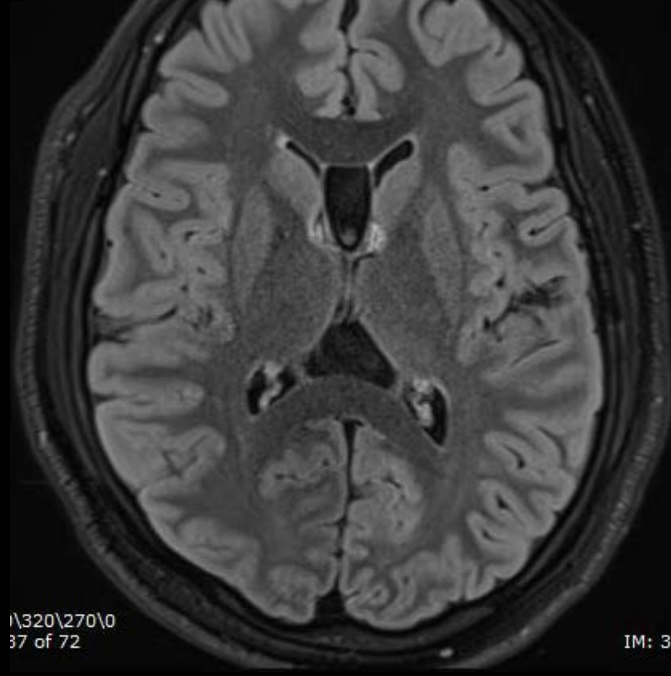
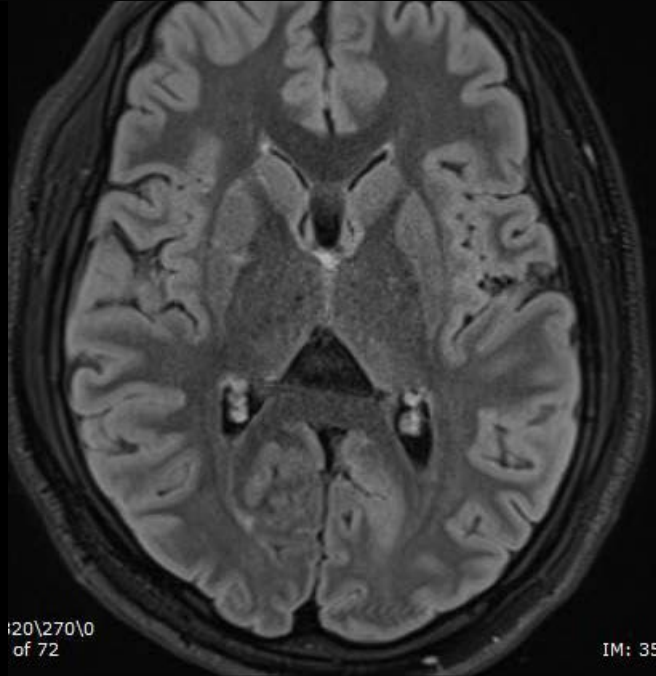
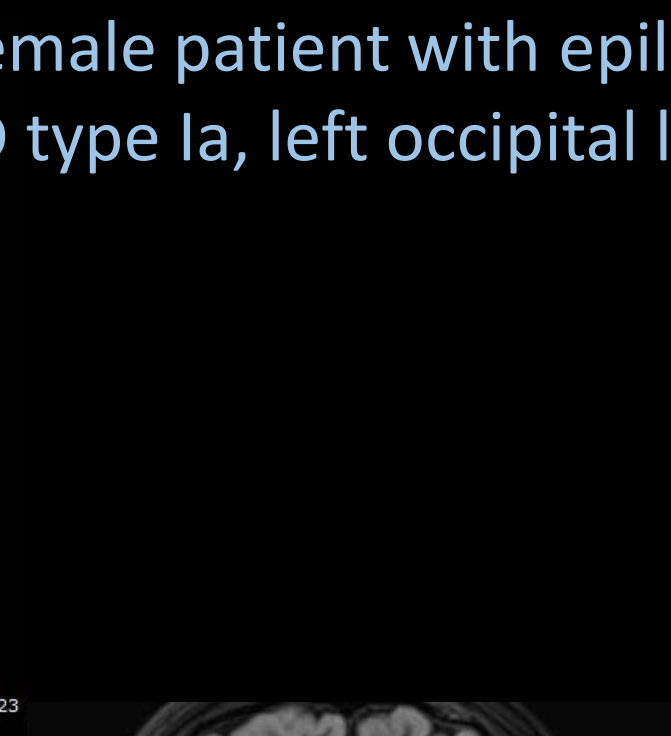
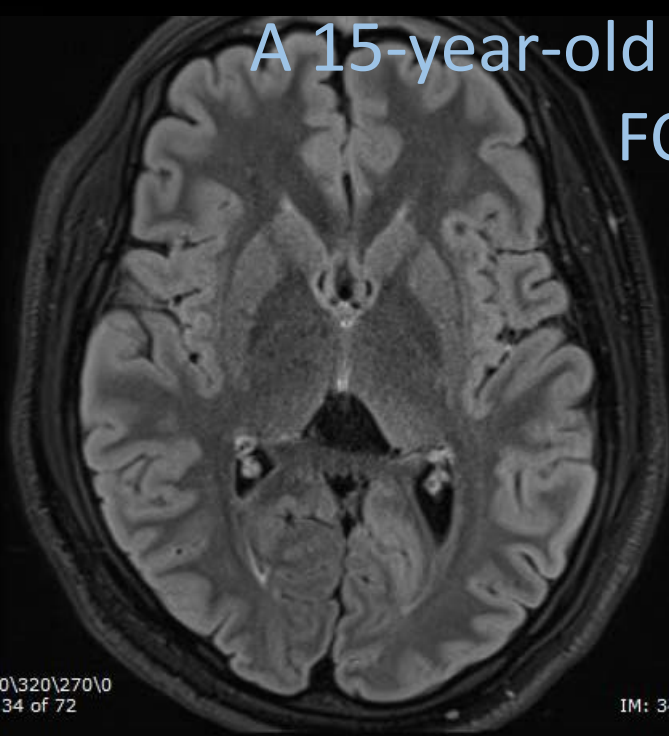
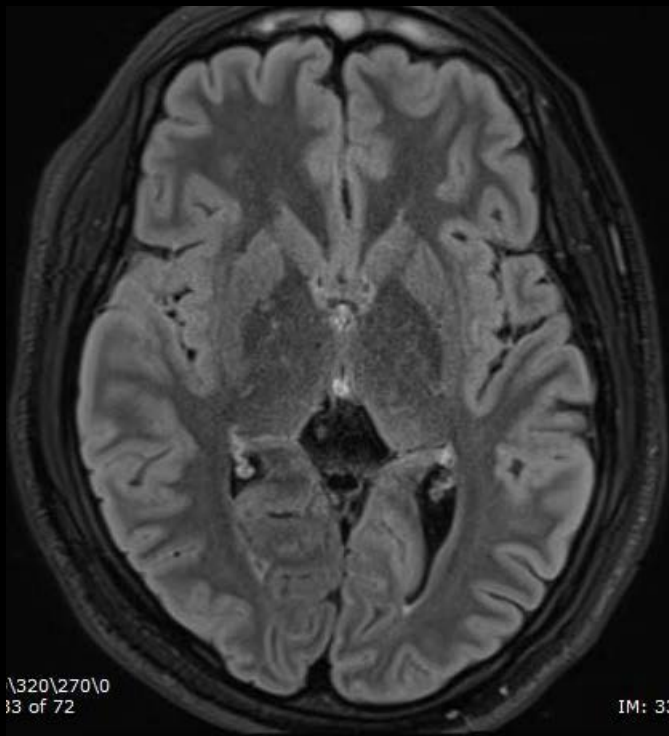
Table 2. New classification system of focal cortical dysplasia by Blumcke et al. 2011.

Type	Characteristic features
I	a – focal cortical dysplasia with abnormal radial cortical lamination b – focal cortical dysplasia with abnormal tangential 6-layer cortical lamination c – focal cortical dysplasia with abnormal radial and tangential cortical lamination
II	a – focal cortical dysplasia with dysmorphic neurons b – focal cortical dysplasia with dysmorphic neurons and balloon cells
III	a – architectural distortion of cortical layer in temporal lobe with hippocampal atrophy b – architectural distortion of cortical layer adjacent to glial or glioneuronal tumor c – architectural distortion of cortical layer adjacent to vascular malformation d – architectural distortion of cortical layer adjacent to other lesions acquired in early childhood such as trauma, ischemic event, encephalitis

FCD TYPE I

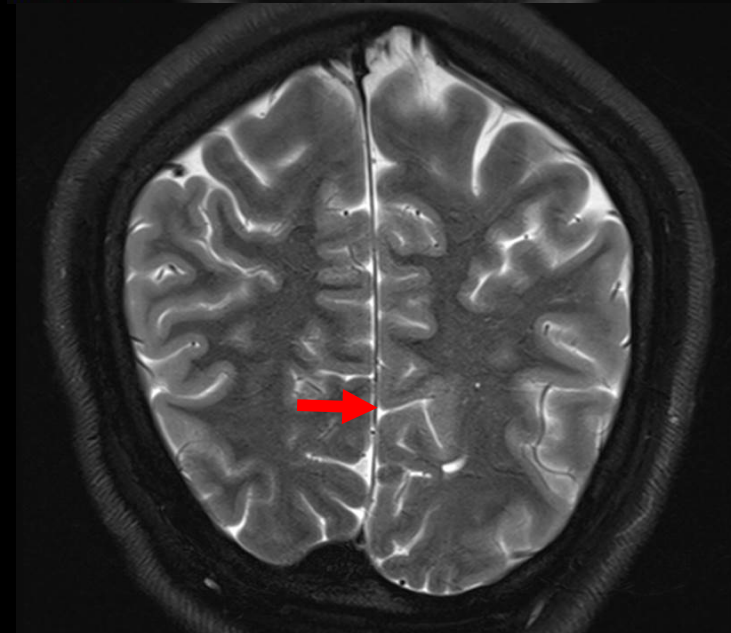
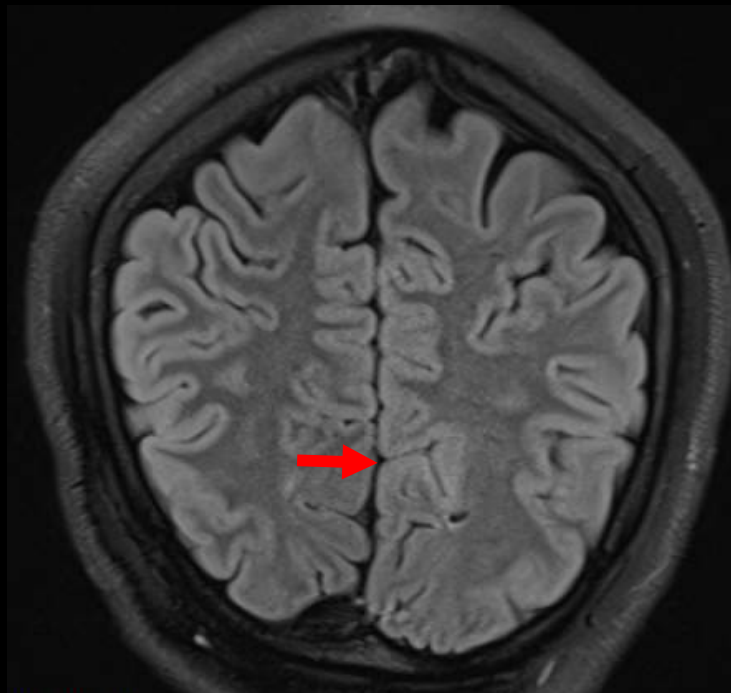
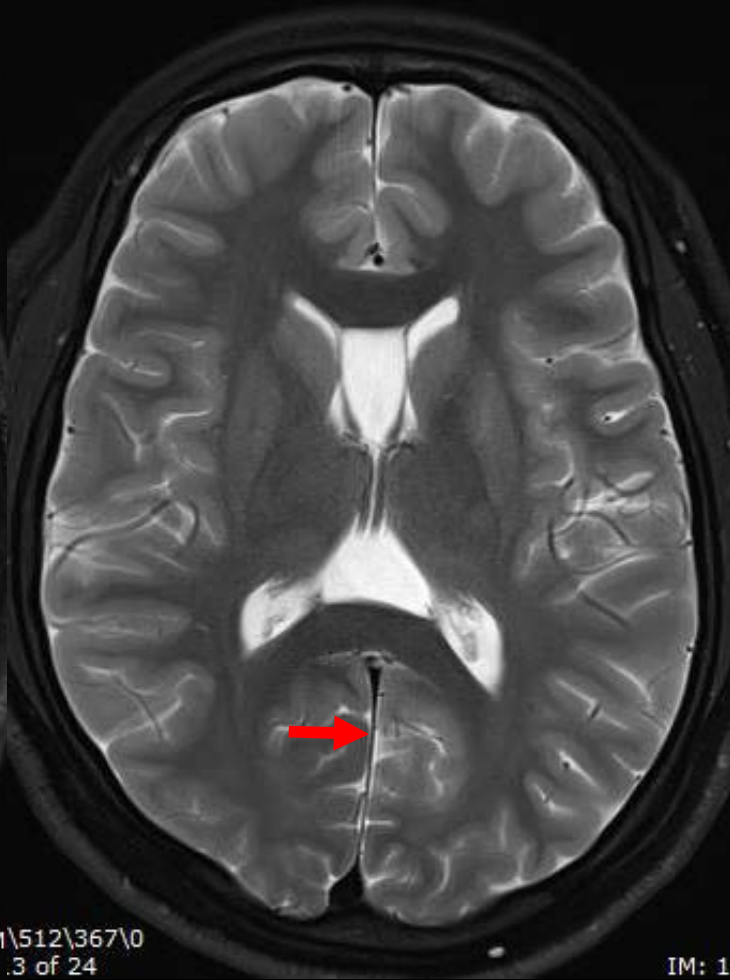
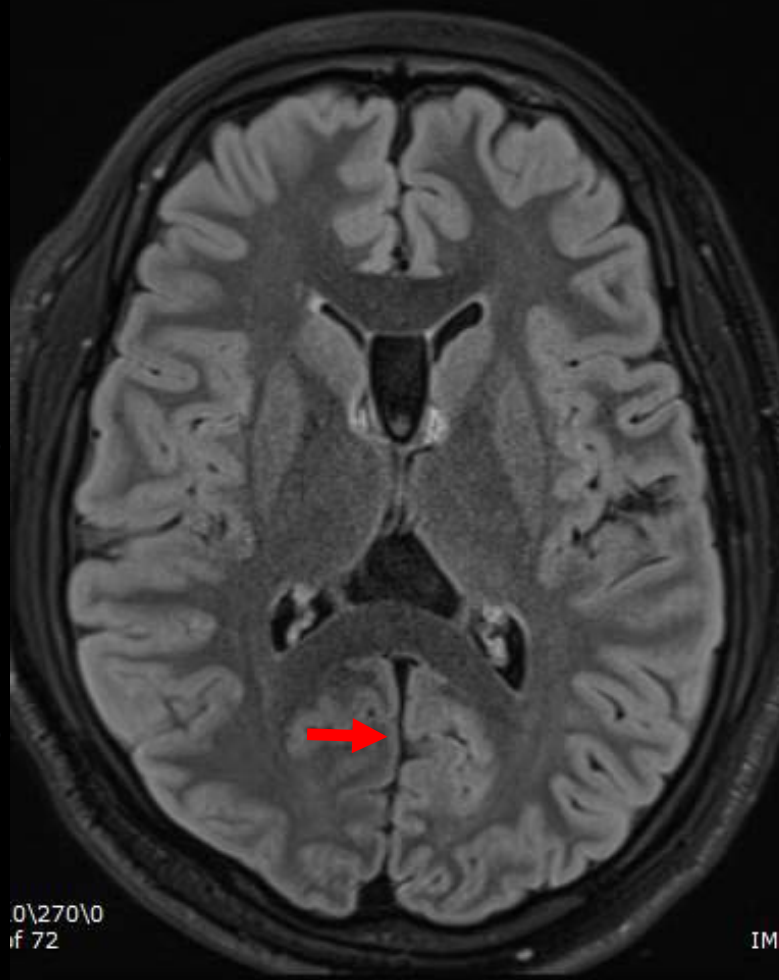
- Significant segmental or lobar hypoplasia/atrophy
- Often with reduced volume of subcortical WM, which may reveal increased signal on T2WI/FLAIR and decreased on T1WI/IR.
- Slight blurring of GM/WM junction
- Abnormal sulcal and gyral pattern
- Frequently found in the temporal lobe with coexist hippocampal atrophy (IIIa)

A 15-year-old female patient with epilepsy
FCD type Ia, left occipital lobe.

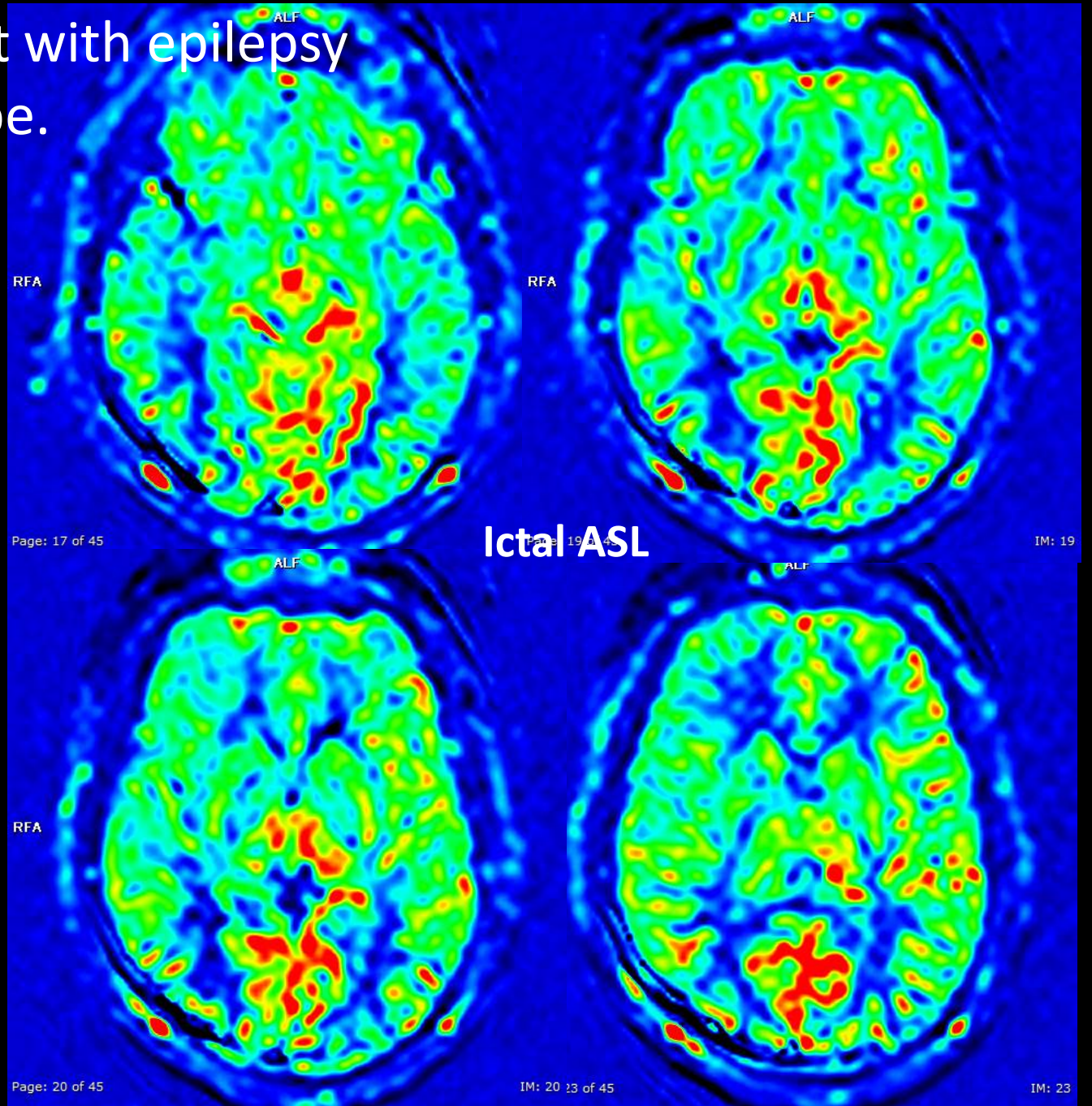
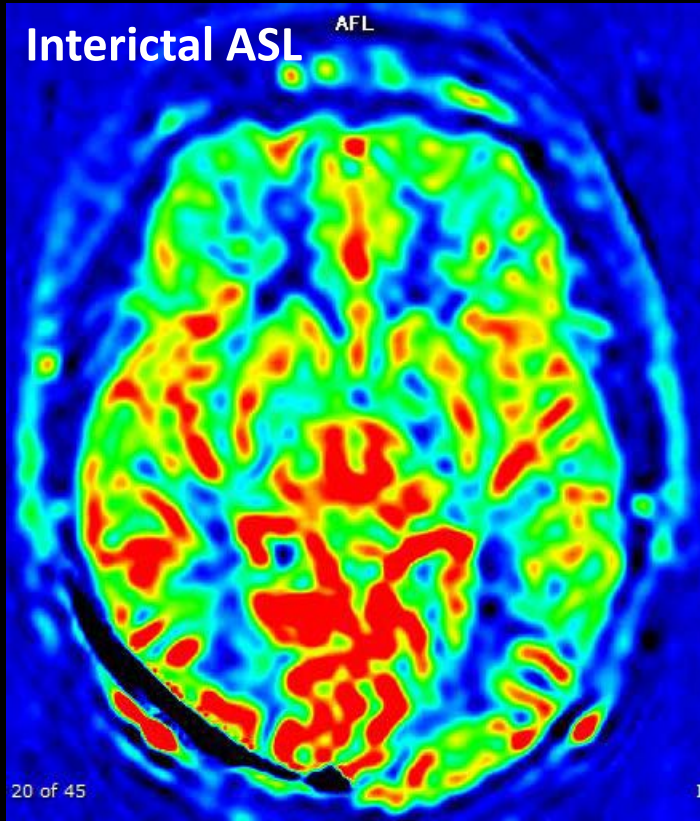


IM: 37

A 15-year-old female patient with epilepsy
FCD type Ia, left occipital lobe.



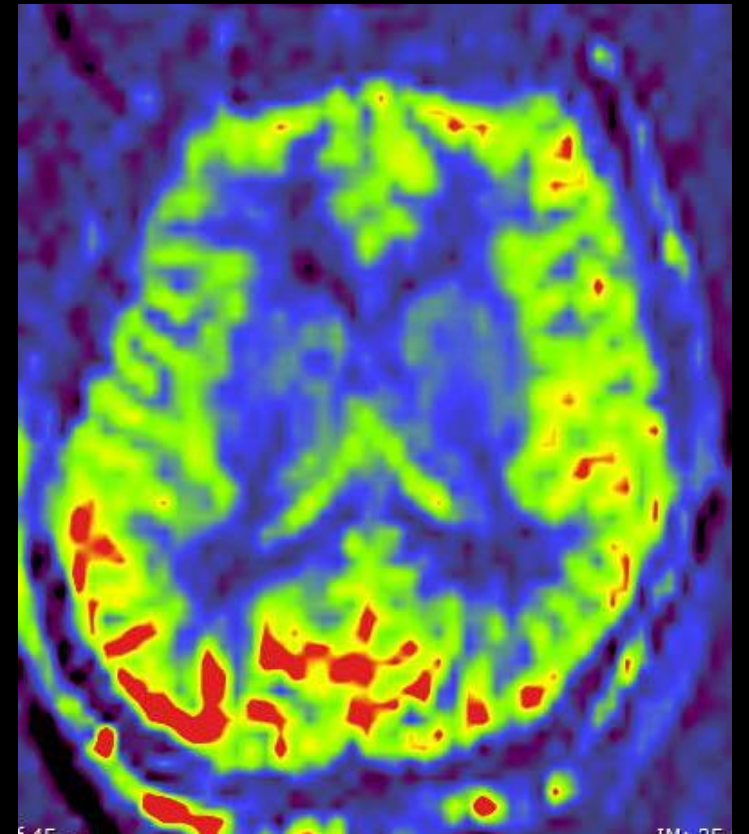
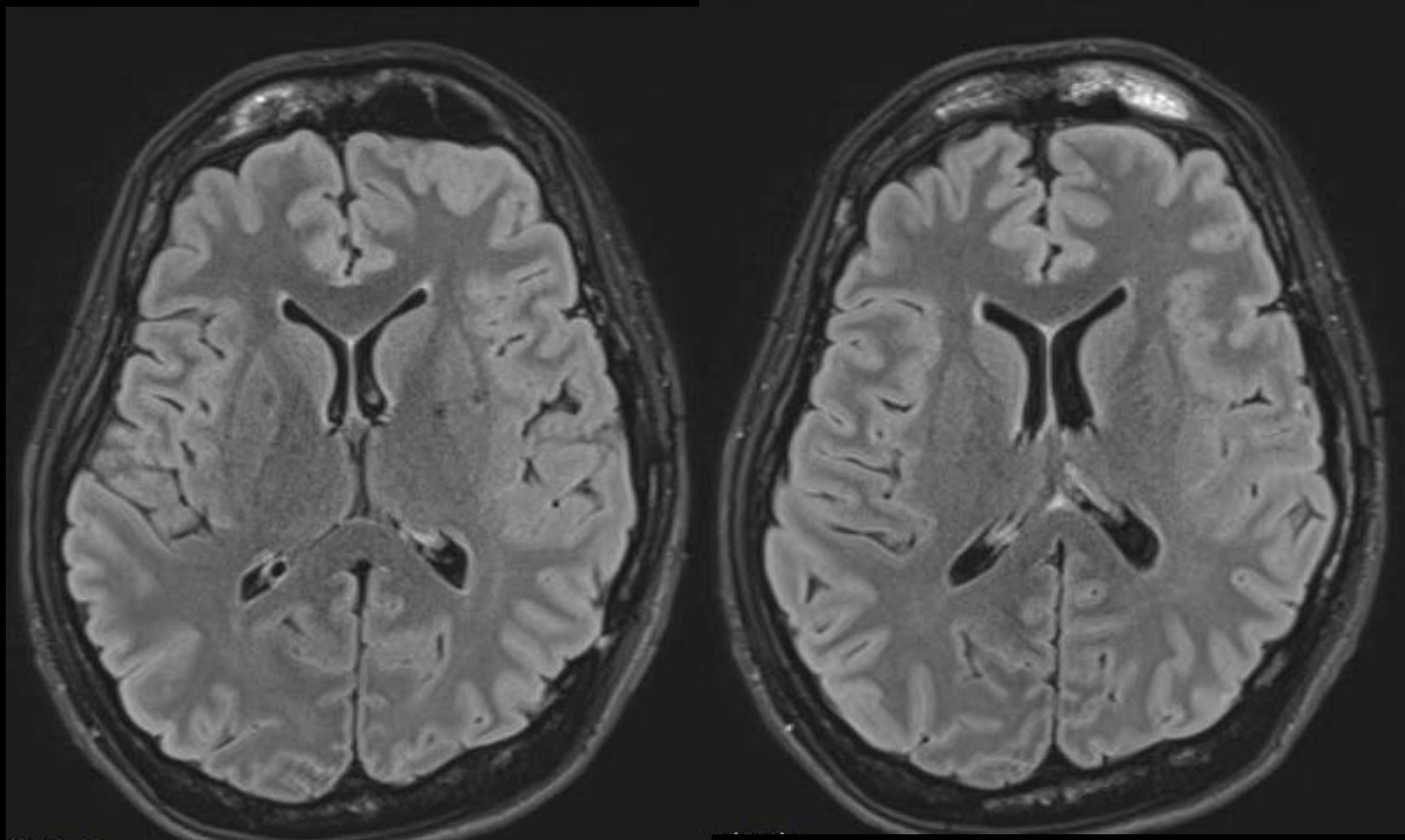
A 15-year-old female patient with epilepsy
FCD type Ia, left occipital lobe.



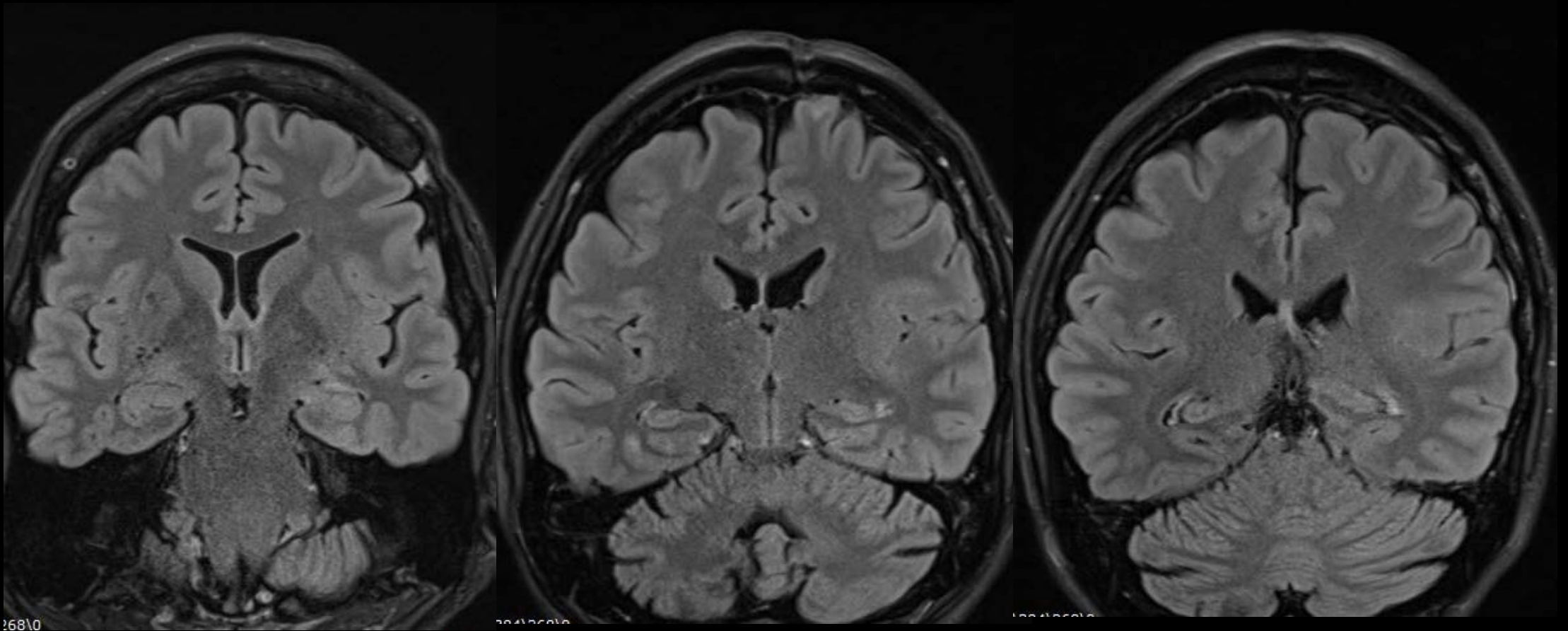
FCD TYPE II

- Cortical thickening
- Marked blurring of GM/WM junction (more evident than in type I)
- An increase WM signal on T2WI, FLAIR (more evident than in type I) and decrease on T1WI
- Altered WM signal, often towards the ventricle (**transmantle sign**)
- Often abnormal sulci, gyri, which clearly visualized by surface 3D
- Perivascular space may be enlarged.
- More often found in extratemporal location, predilection toward **frontal lobe**

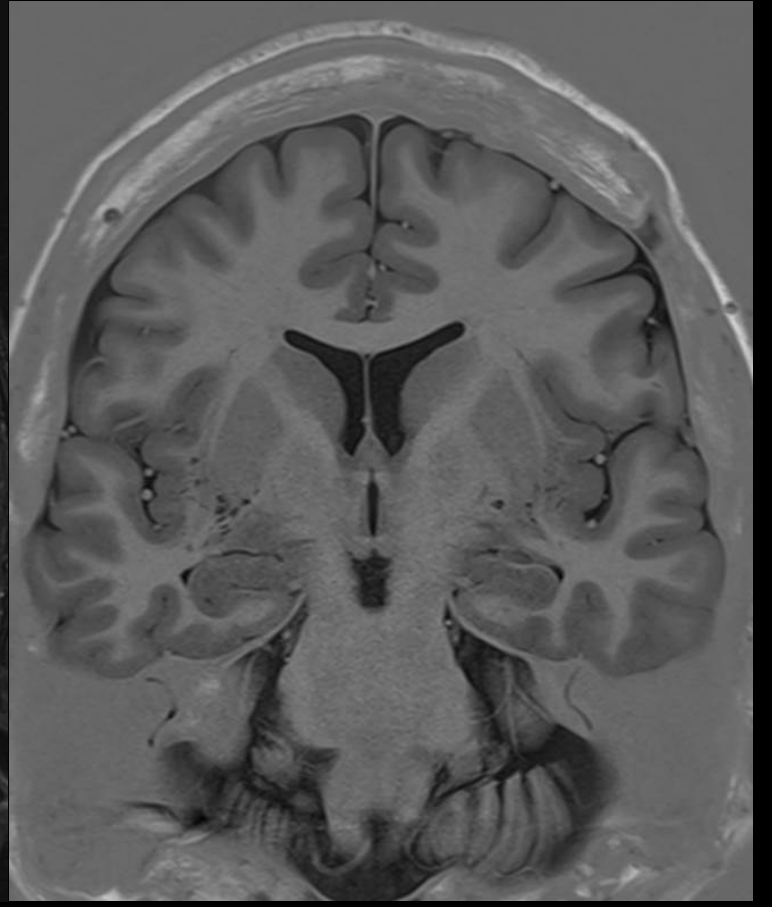
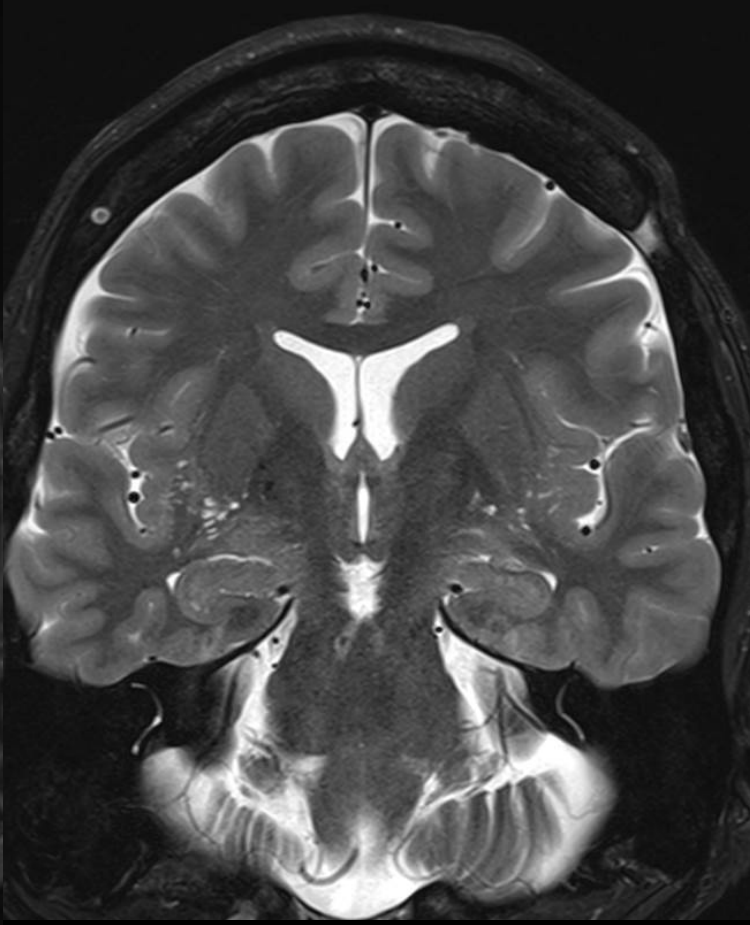
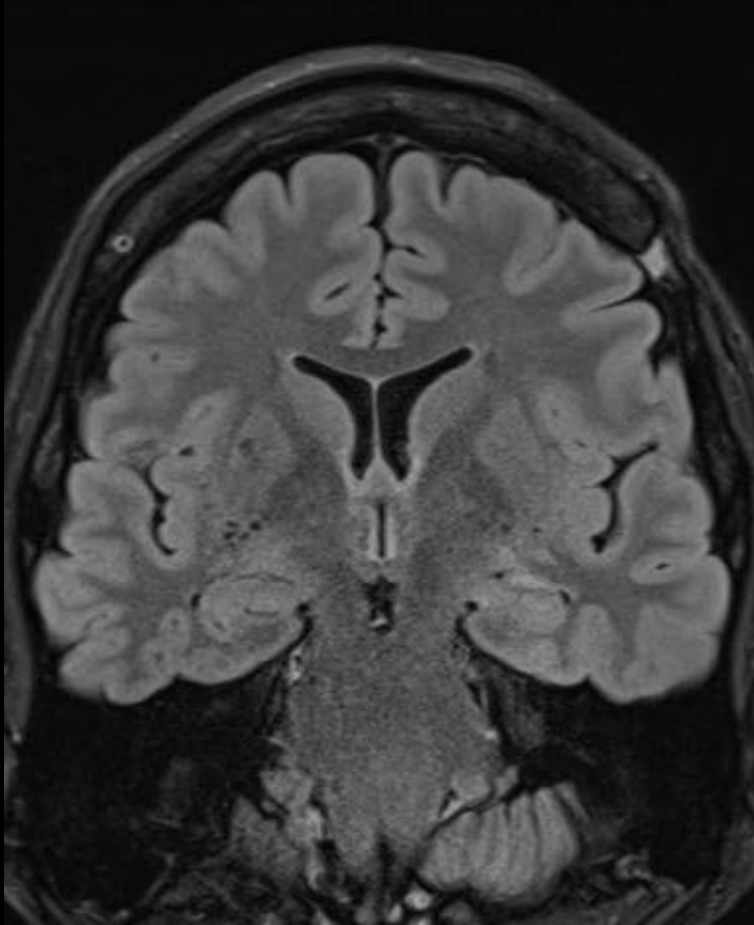
A 36-year-old woman with refractory seizure.
FCD type IIa, left insular lobe.



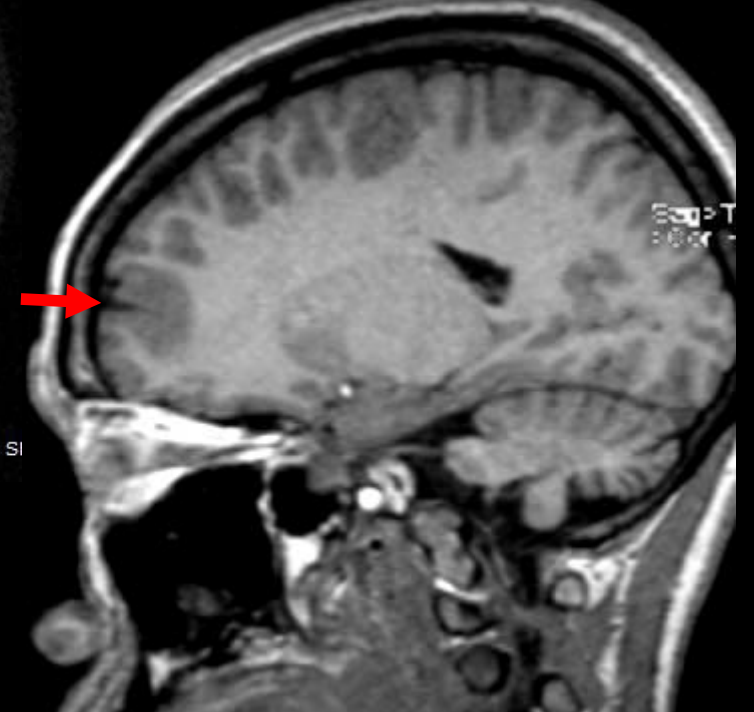
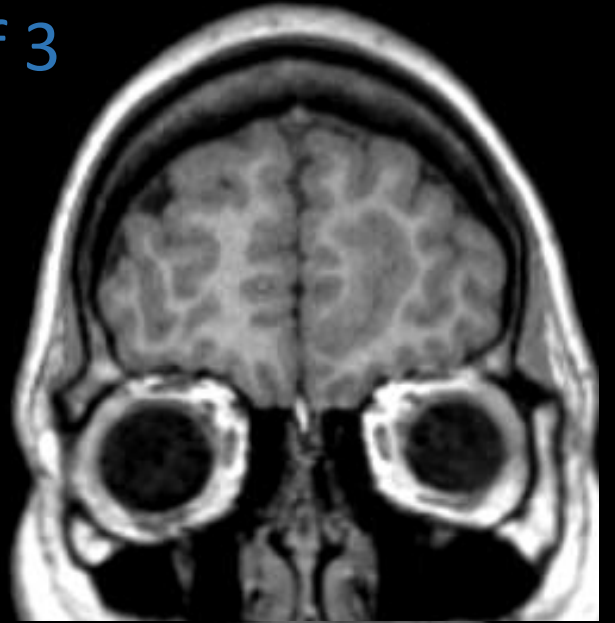
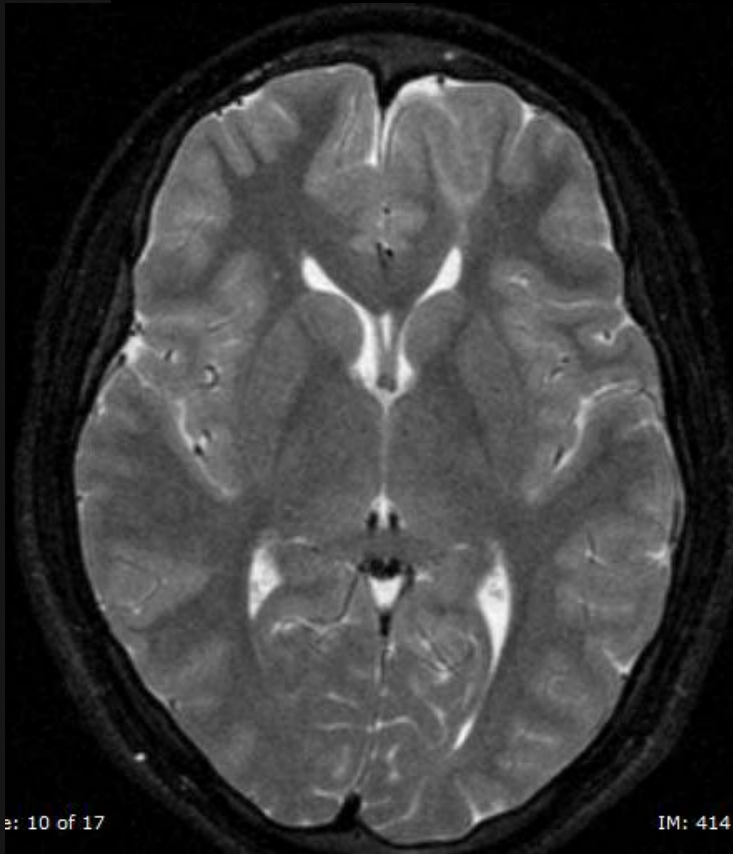
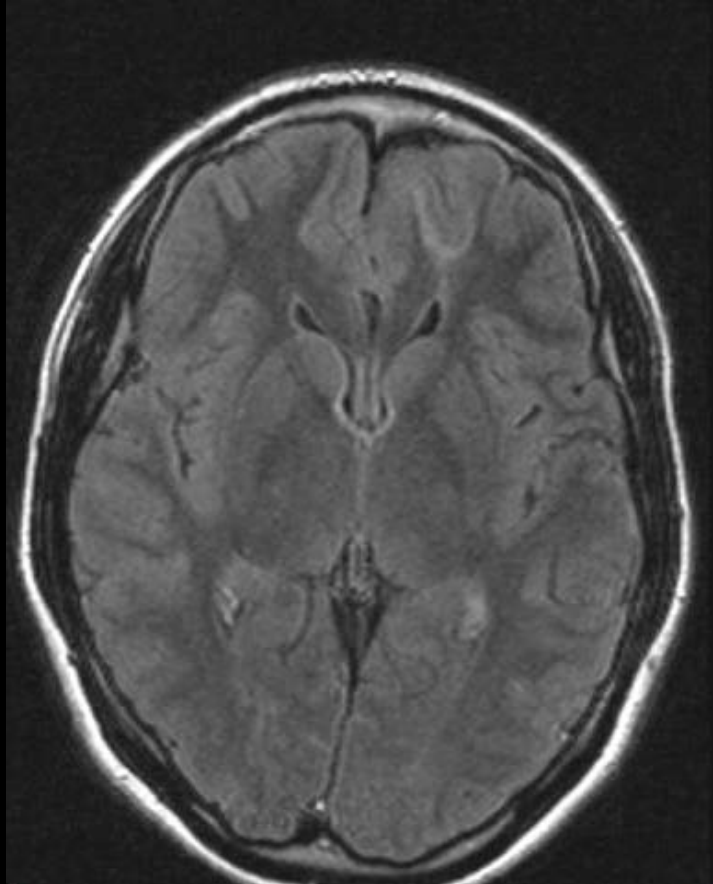
A 36-year-old woman with refractory seizure.
FCD type IIa, left insular lobe.



A 36-year-old woman with refractory seizure.
FCD type IIa, left insular lobe.

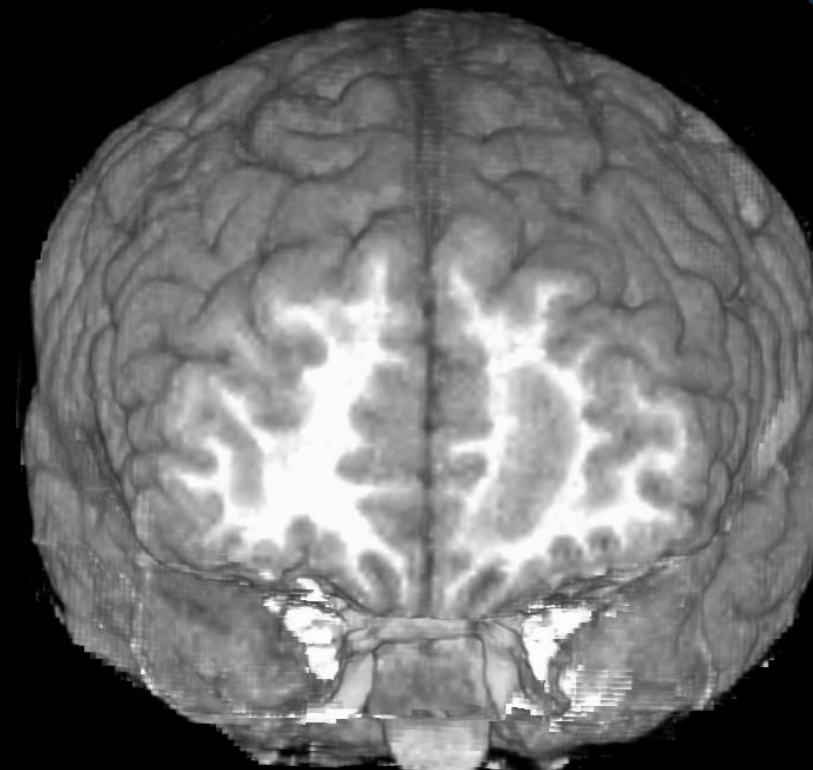
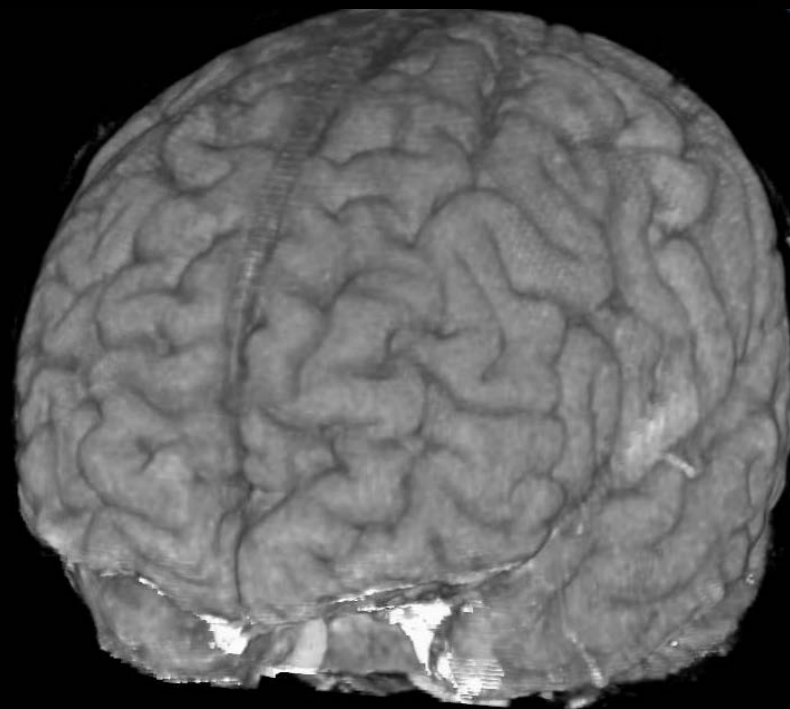
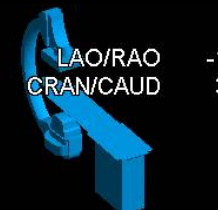

A 16-year-old woman with seizure since the age of 3
FCD type IIb, left frontal lobe



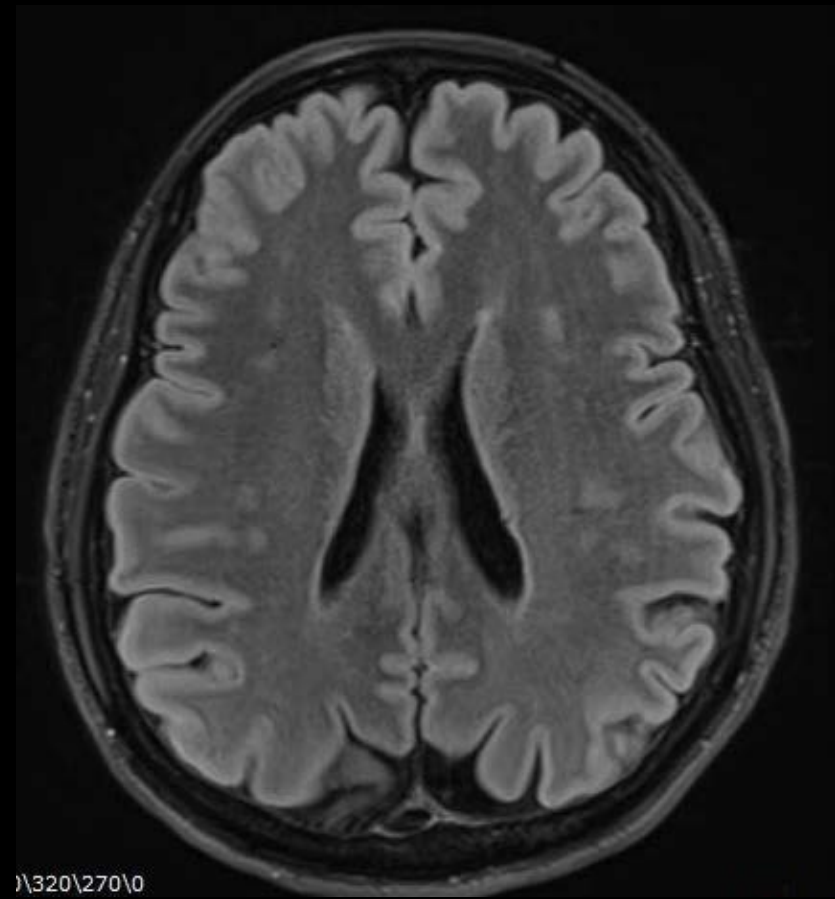
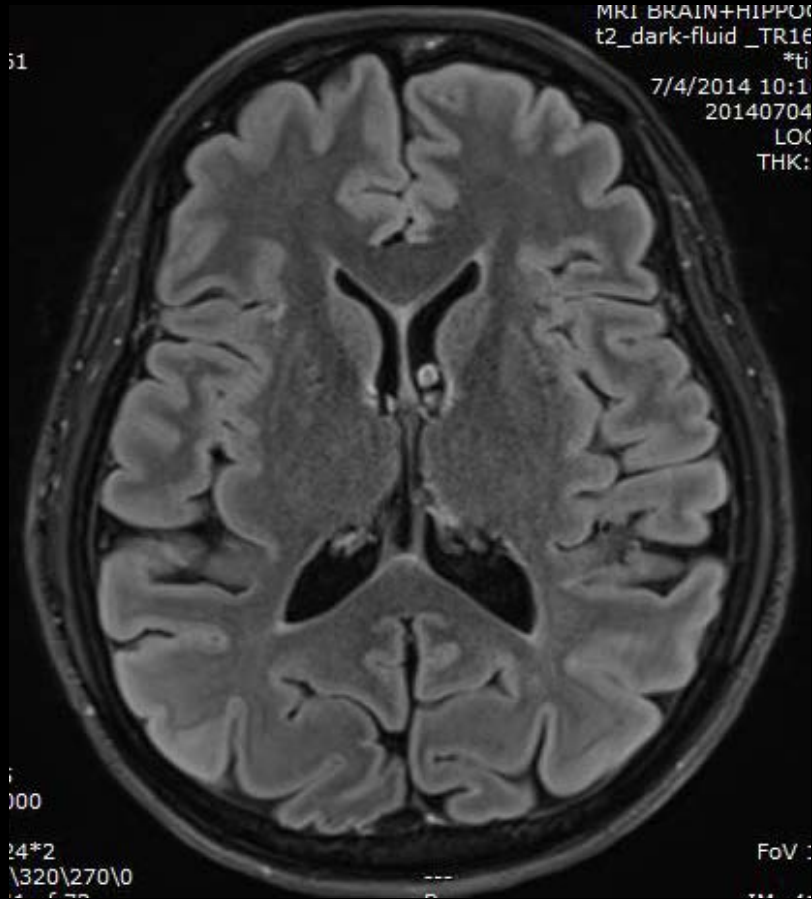
A 16-year-old woman with seizure since the age of 3
FCD type IIb, left frontal lobe

H



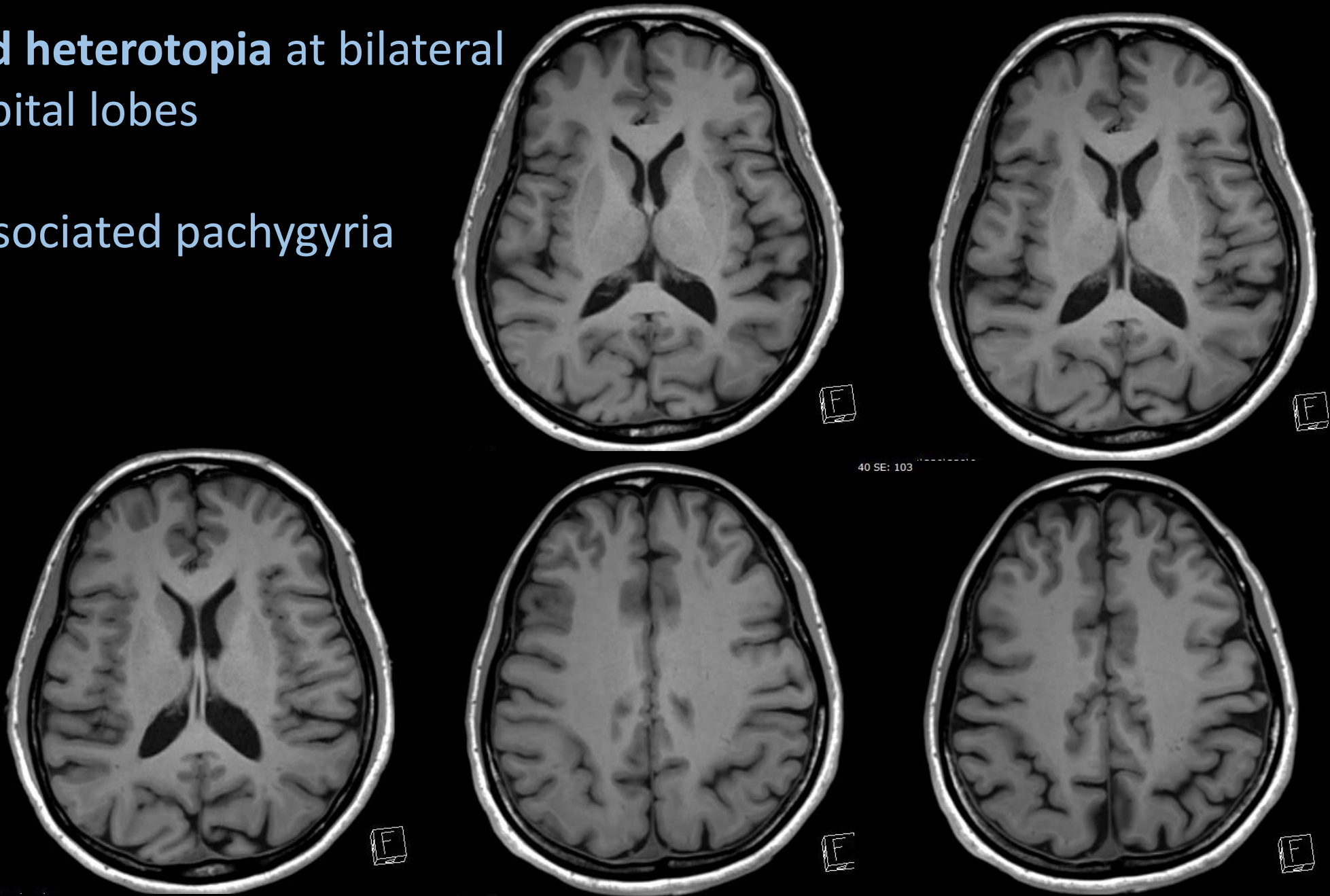
L



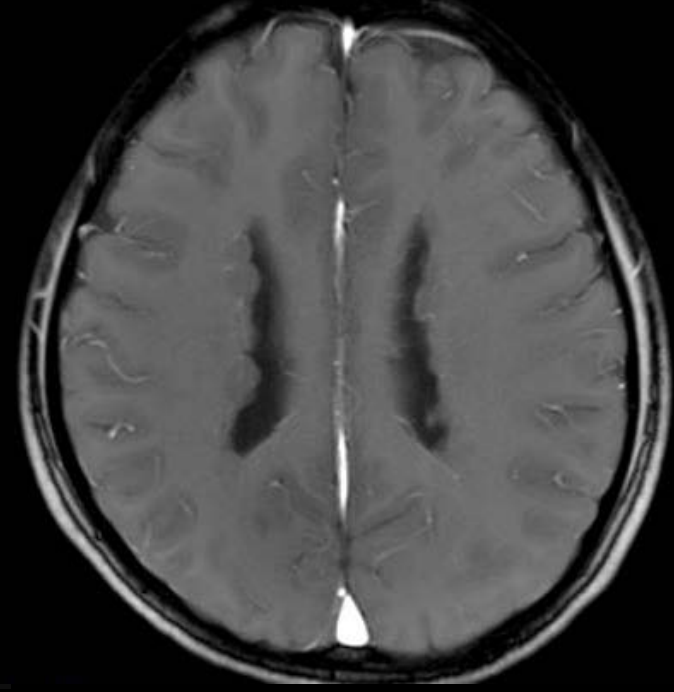
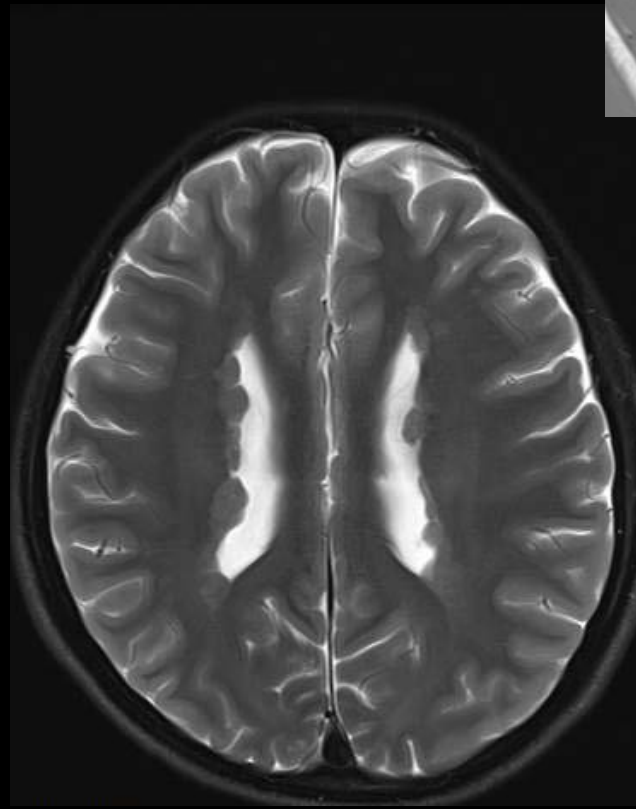
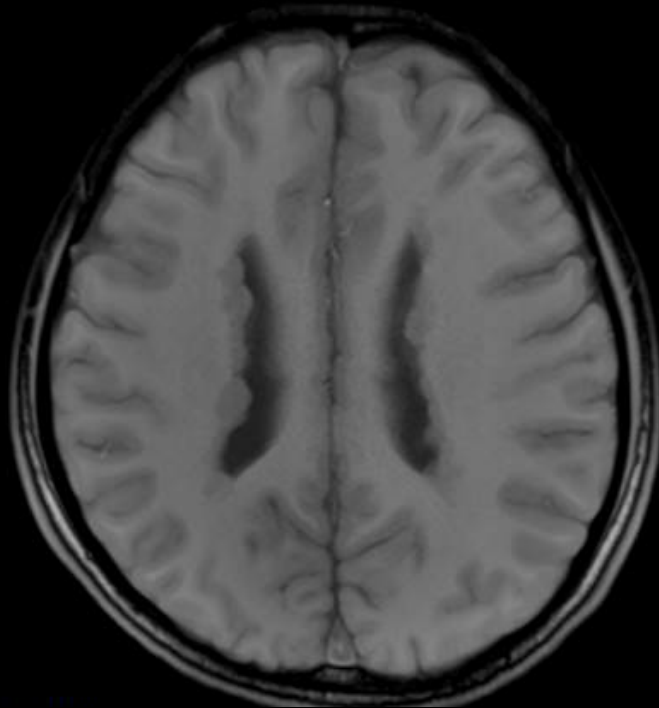
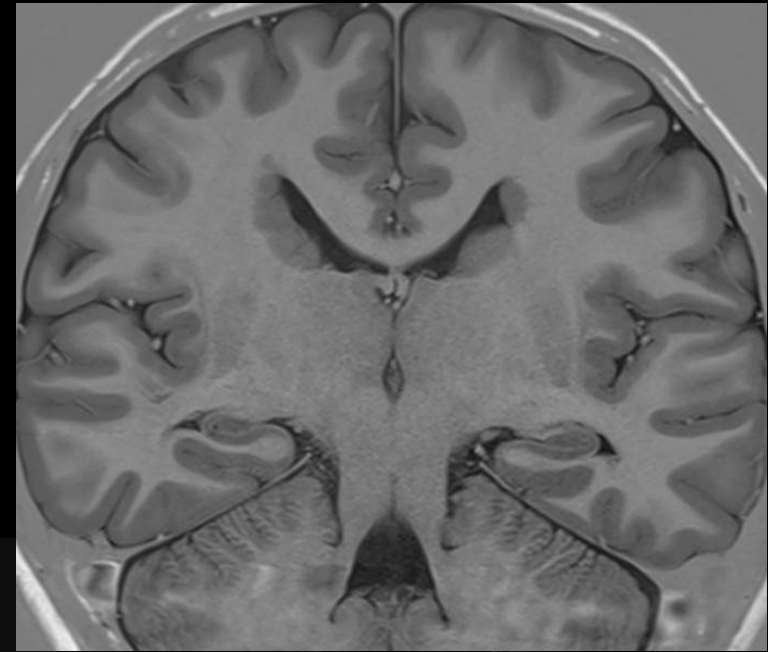


Band heterotopia at bilateral occipital lobes

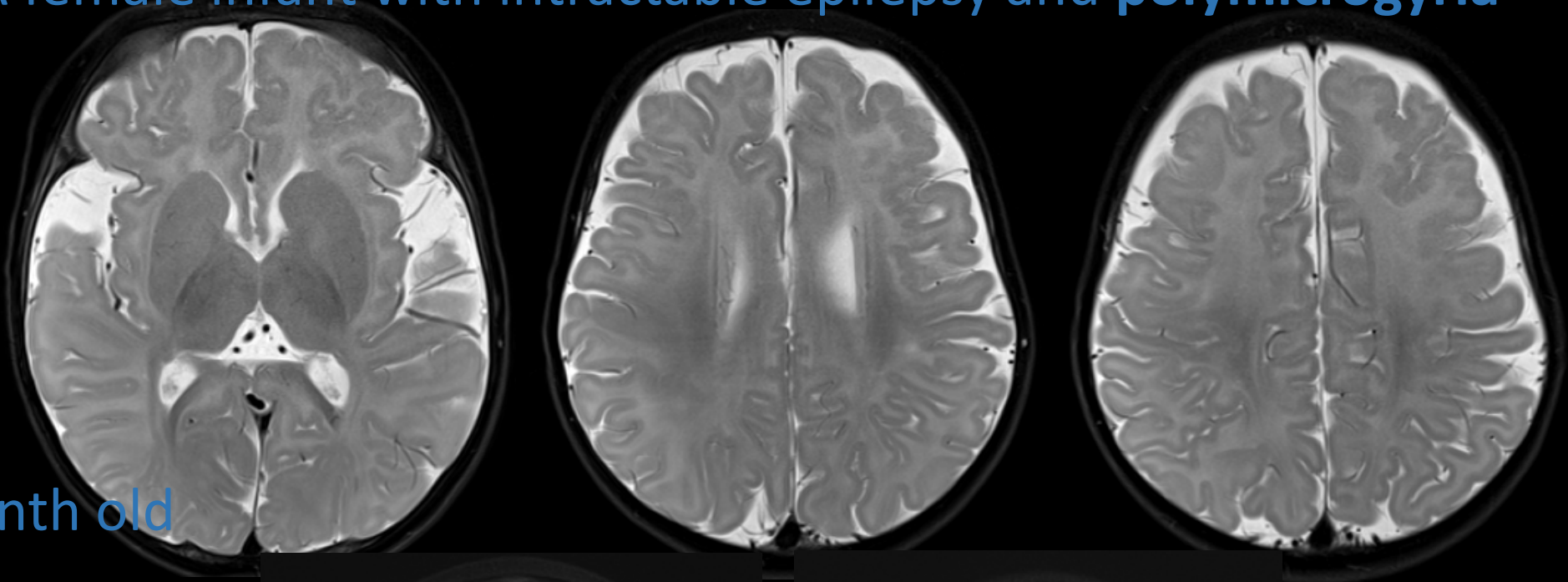
*** Associated pachygyria**



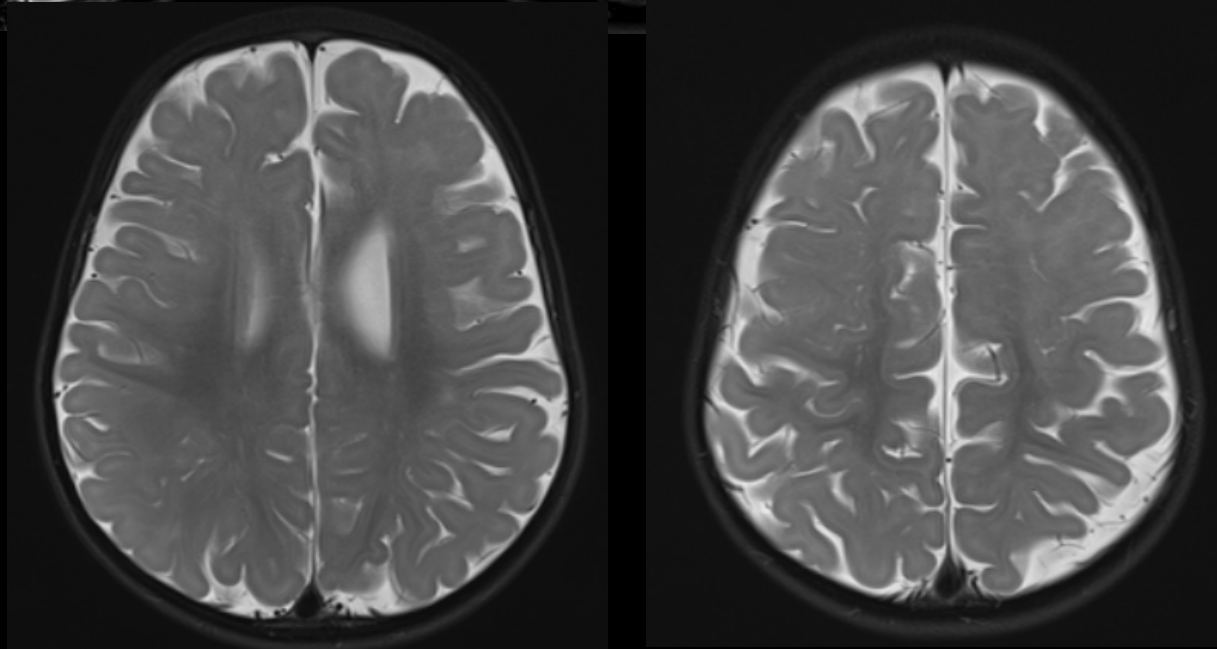
A 15-year-old female patient with epilepsy and subependymal heterotopia



A female infant with intractable epilepsy and **polymicrogyria**

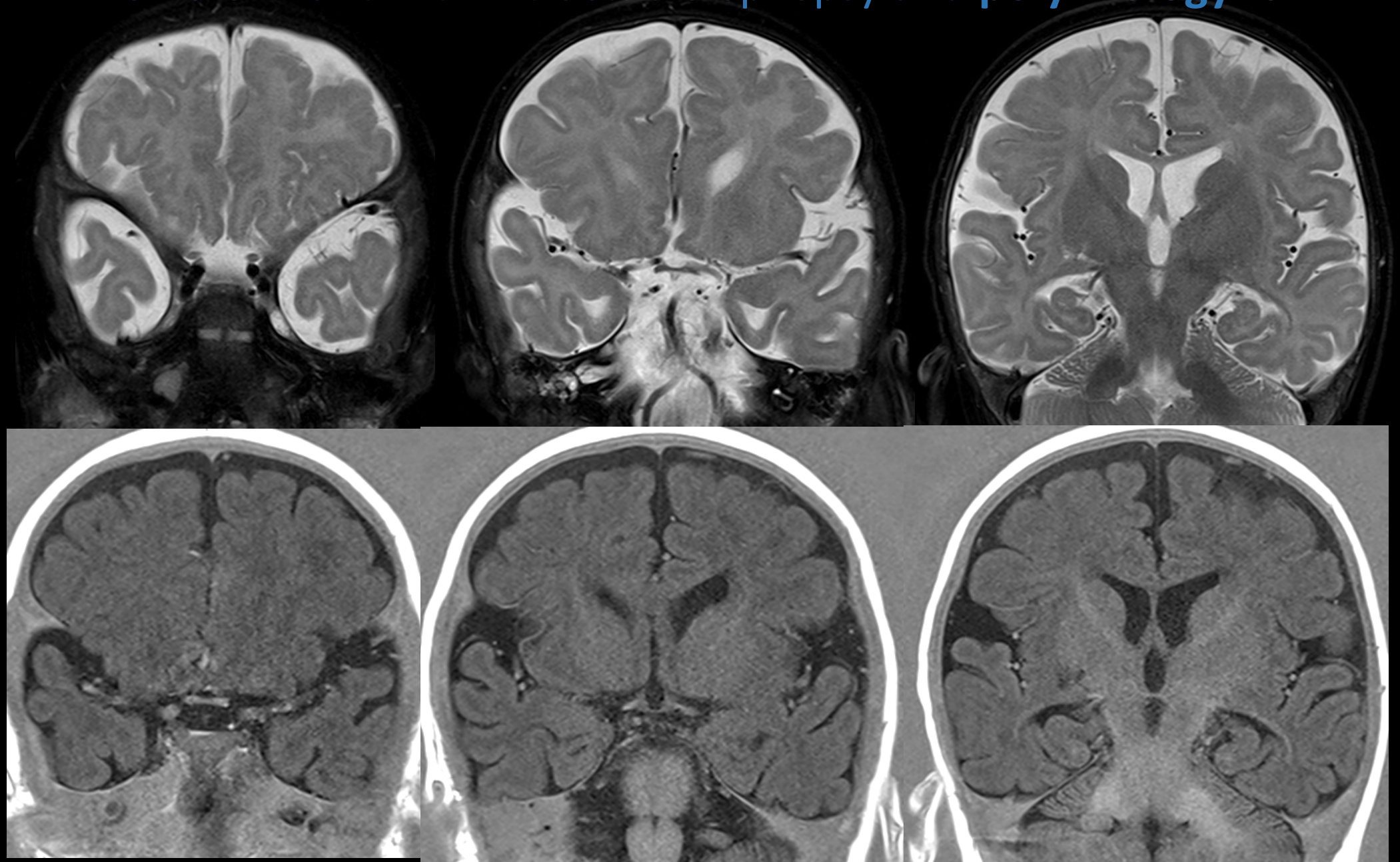


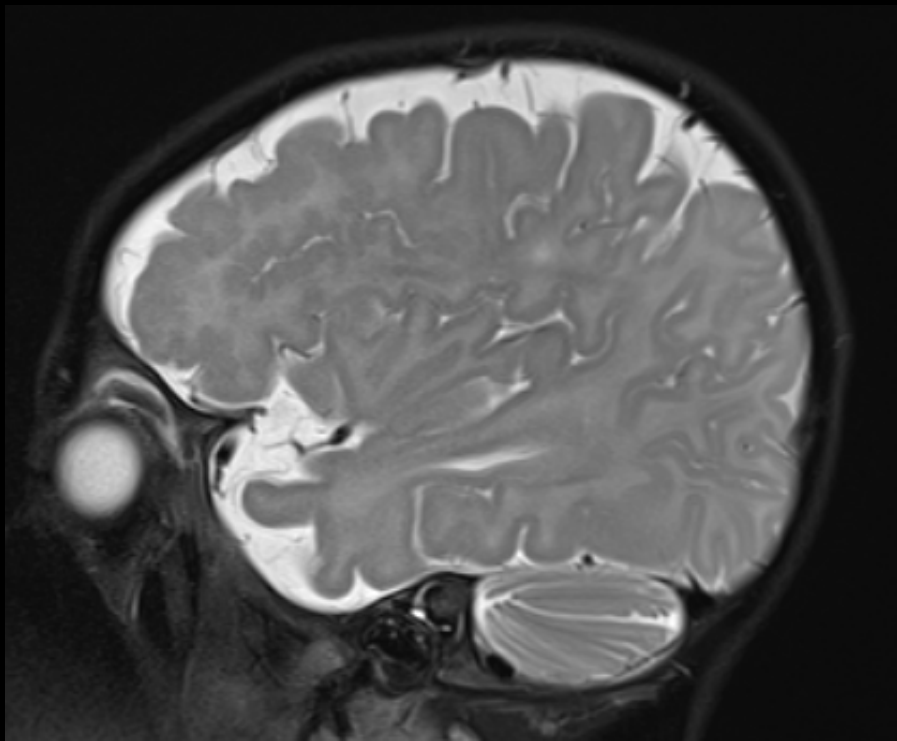
5 month old



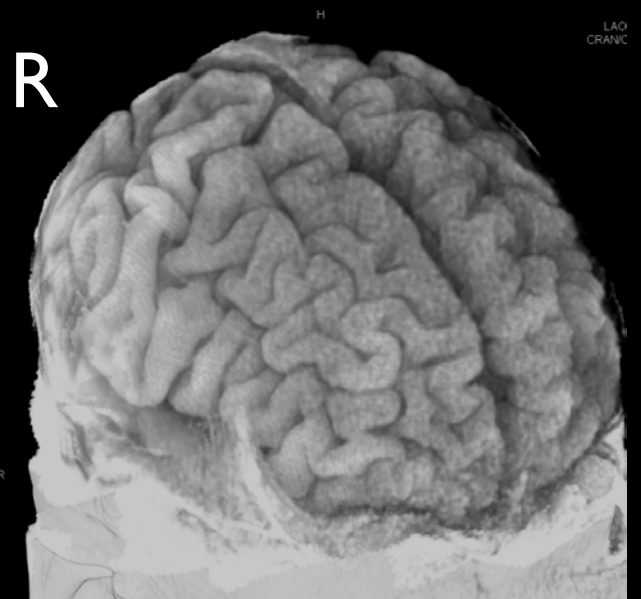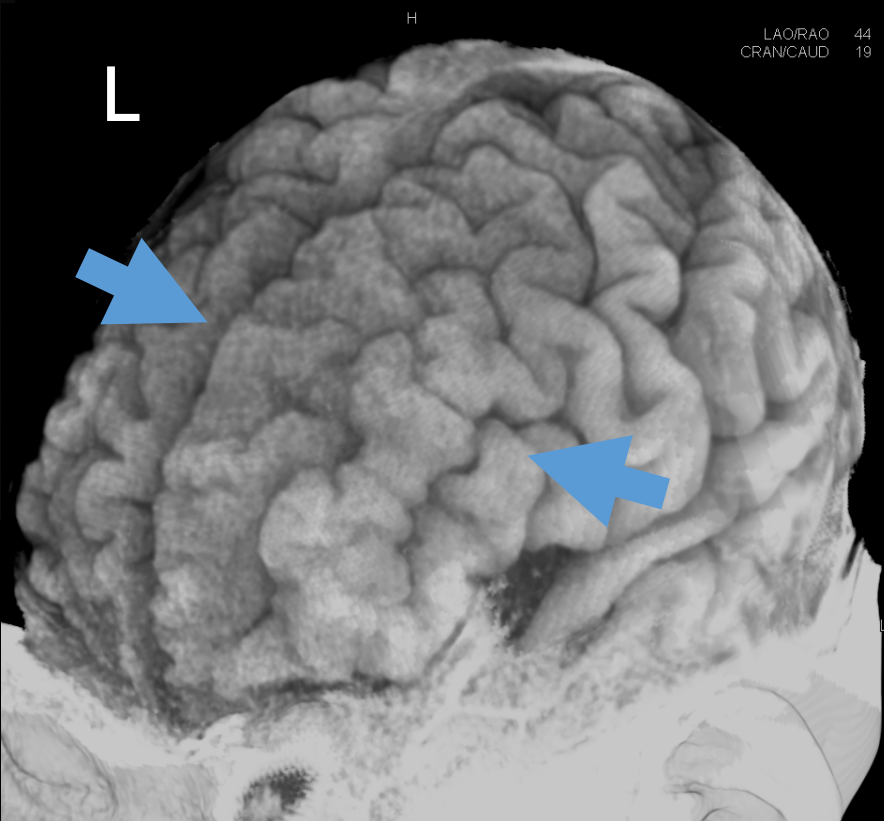
11 month old

A female infant with intractable epilepsy and **polymicrogyria**



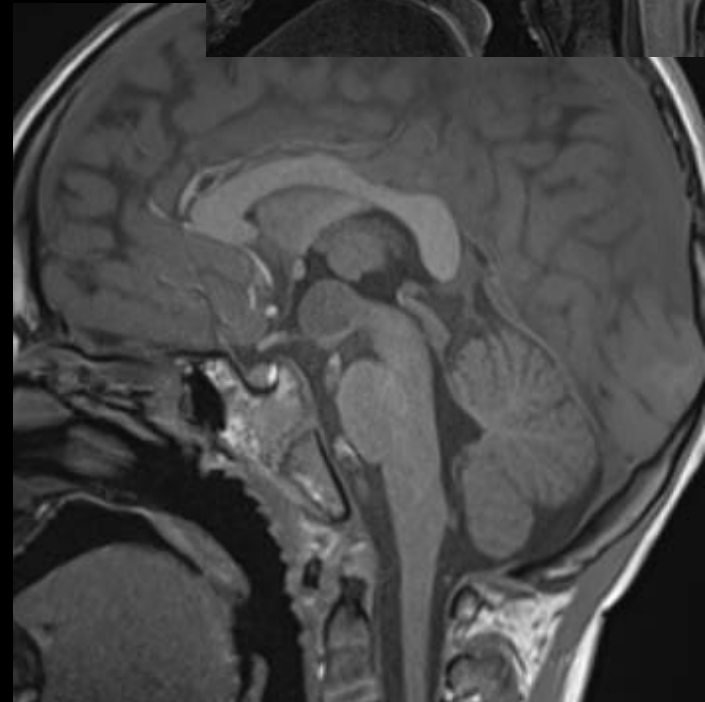
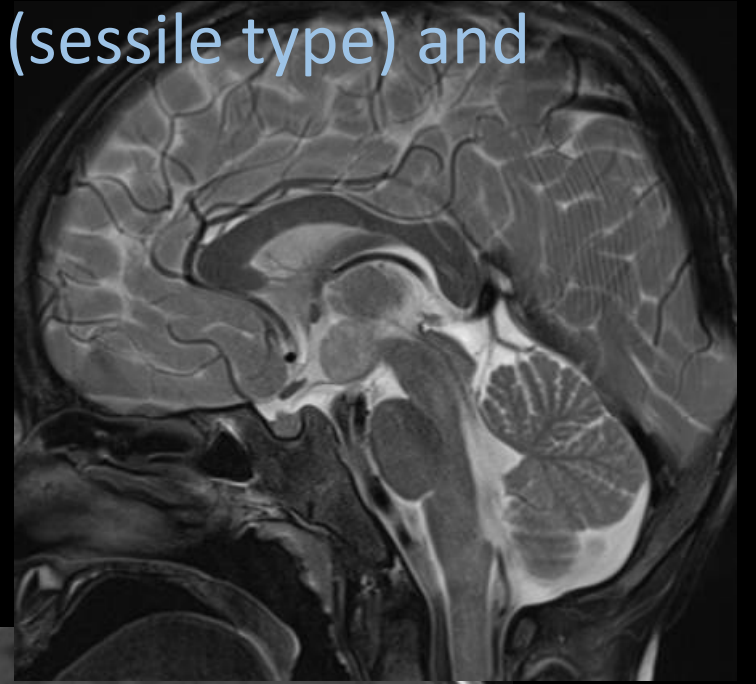
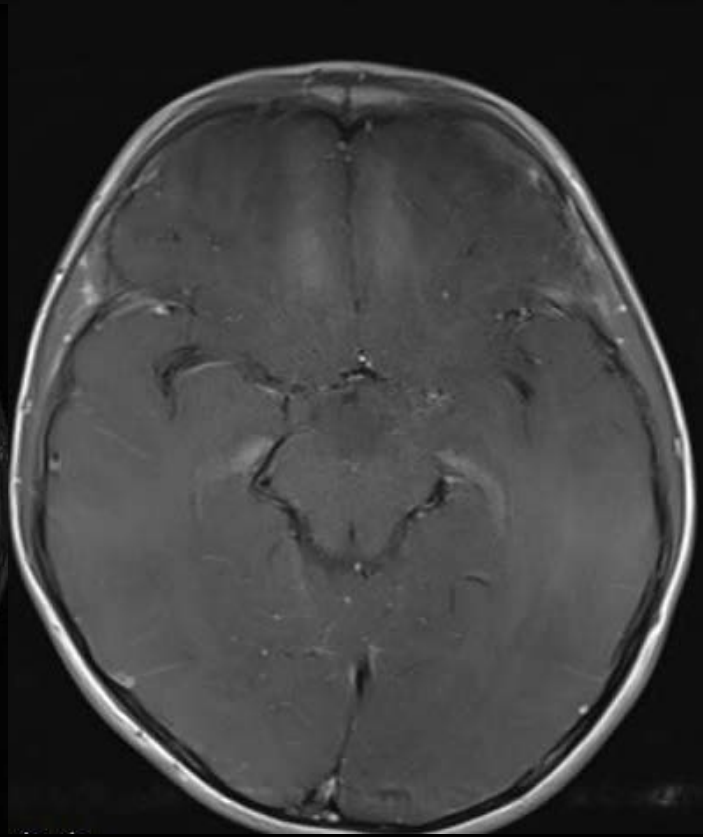
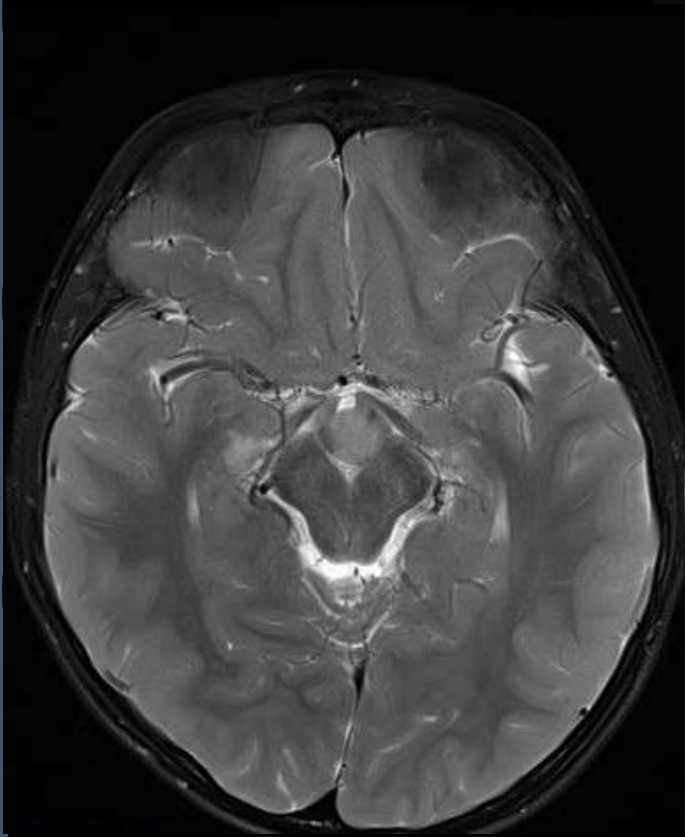


Polymicrogyria

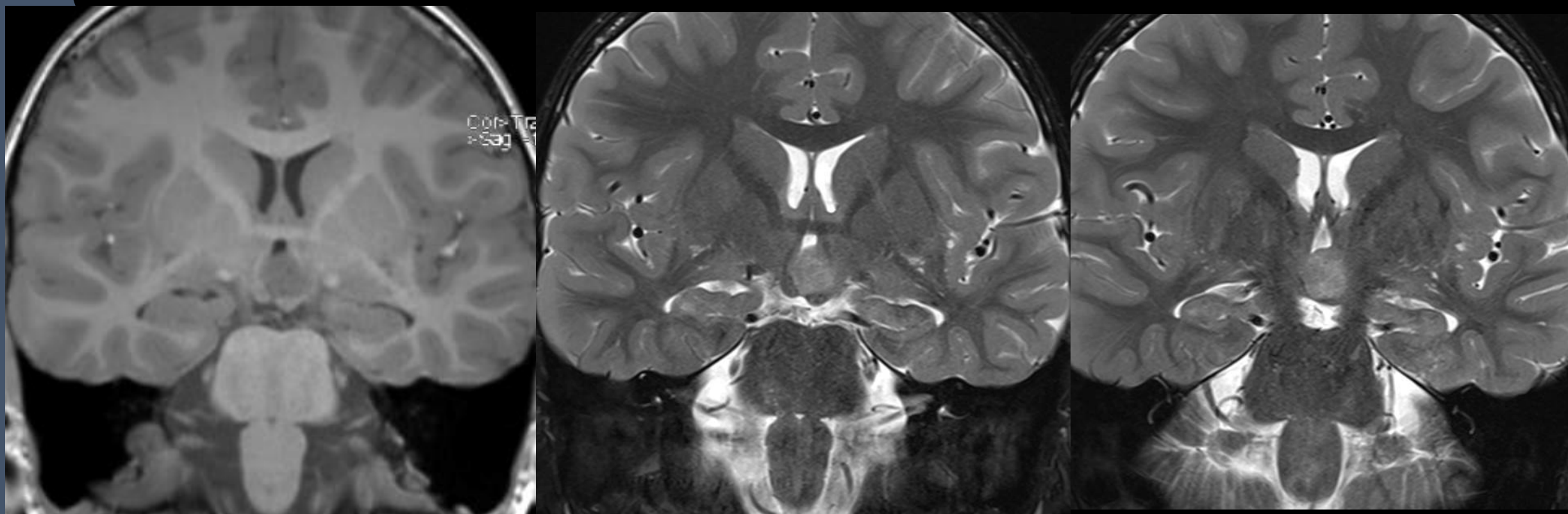


3D MPRAGE (MRI brain)
with 3D reformation

A 4-year-old boy with **hypothalamic hamatoma** (sessile type) and complex partial or gelastic seizure



A 4-year-old boy with hypothalamic hamatoma (sessile type) and complex partial or gelastic seizure

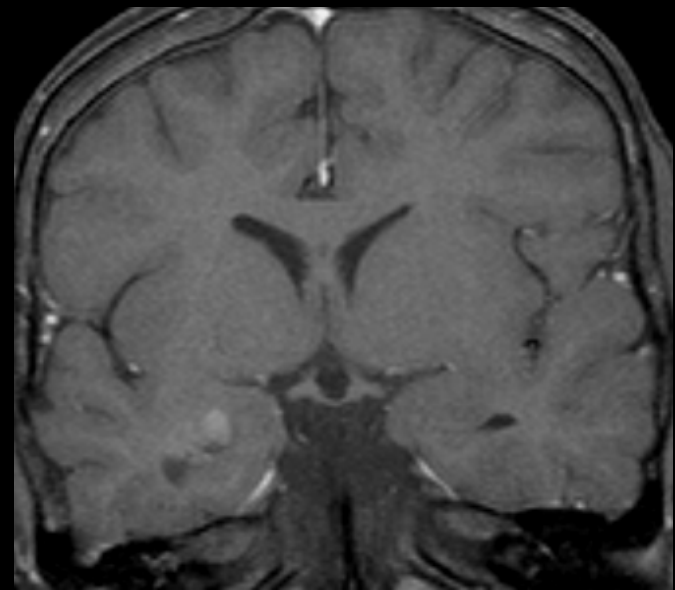
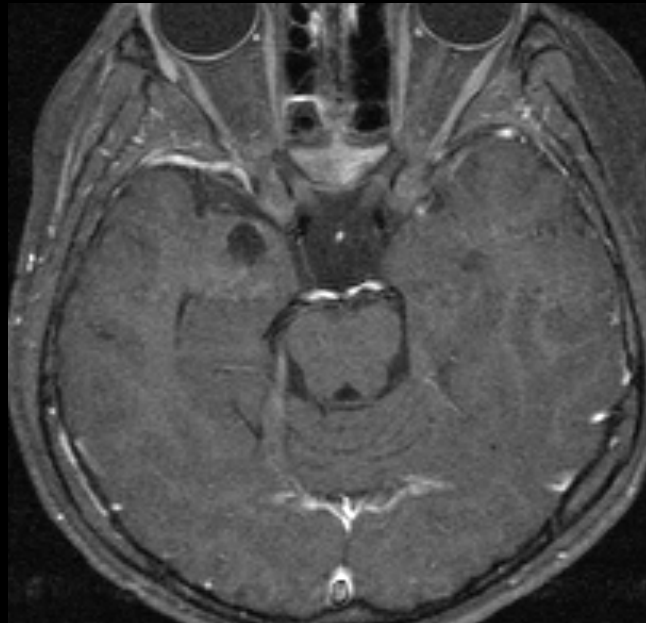
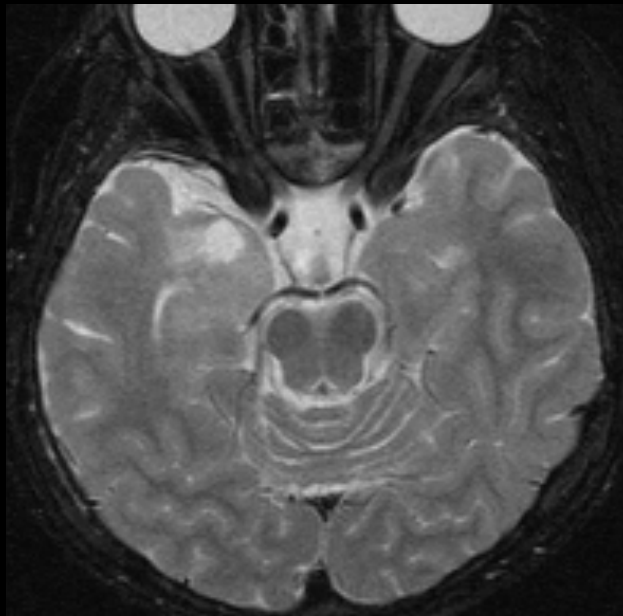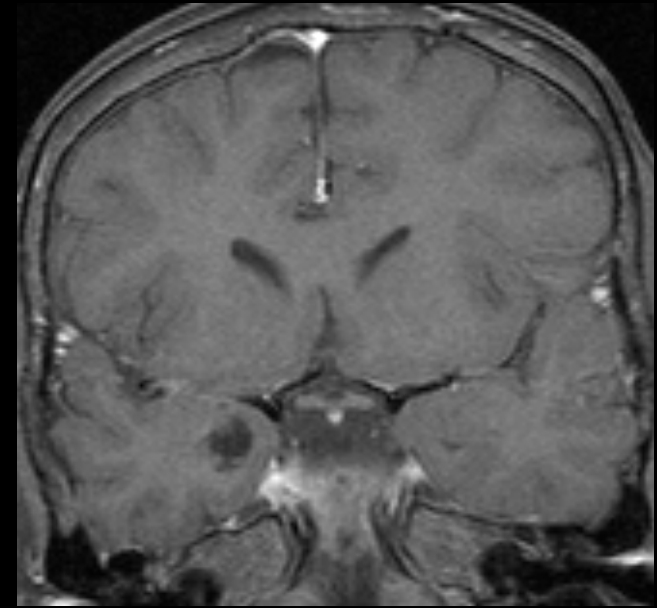
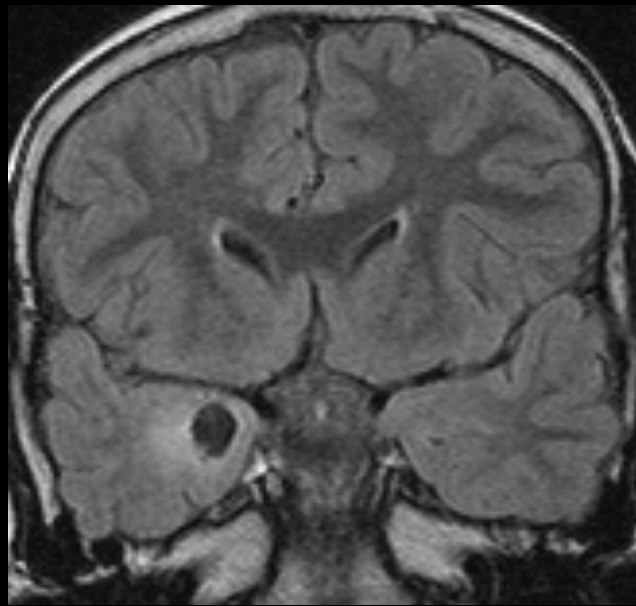


NEOPLASMS

- Involved region: usually temporal lobe (70%), in or adjacent to the cerebral cortex
- MRI 96-99% sensitivity
- Indolent tumors: Ganglioglioma, dysembryoplastic neuroepithelial tumor (DNET), and low-grade gliomas
- Metastasis (elderly, late-onset seizure)
- Chronic recurrent seizures: small, well localized, little or no perilesional edema, +/- mass effect and calvarial remodelling

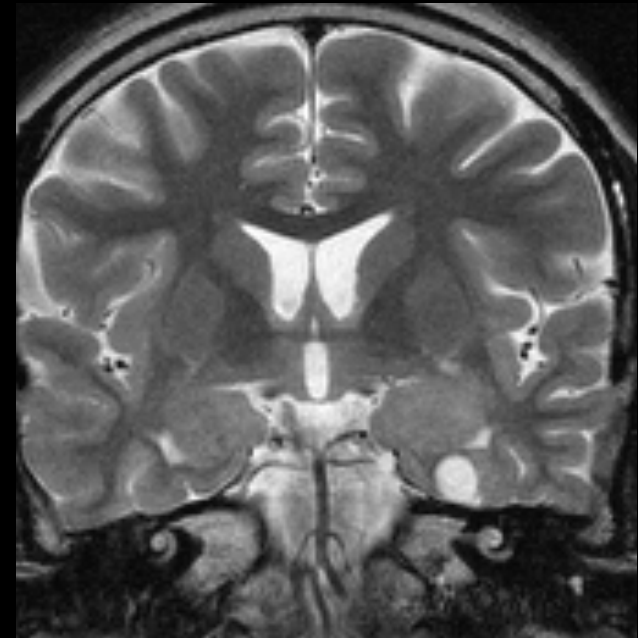
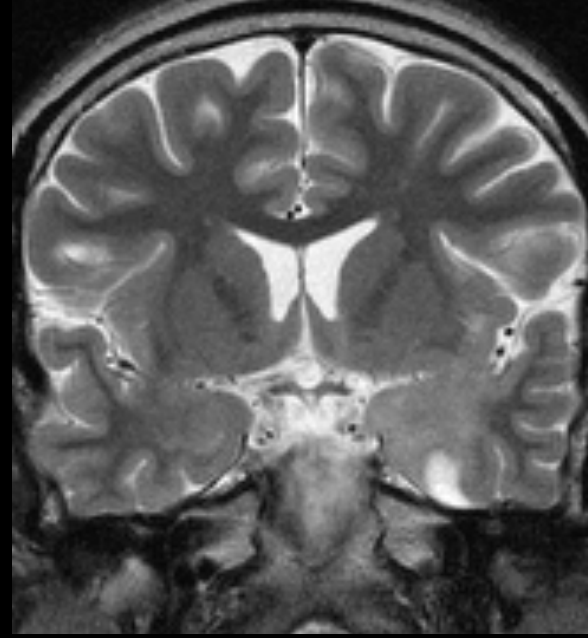
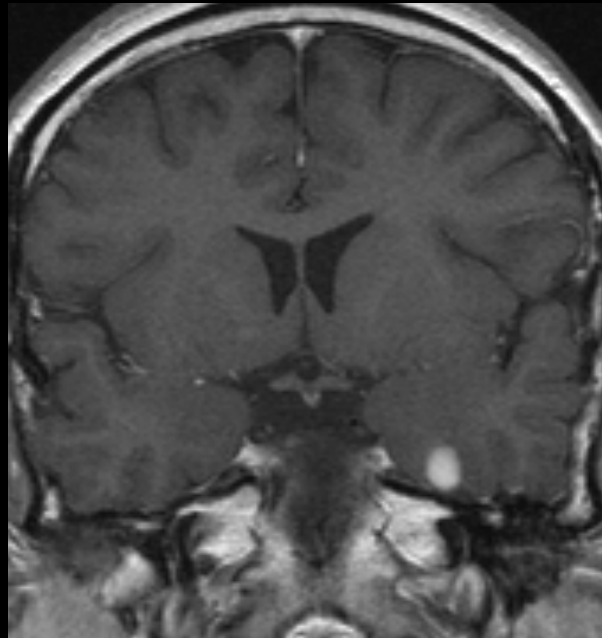
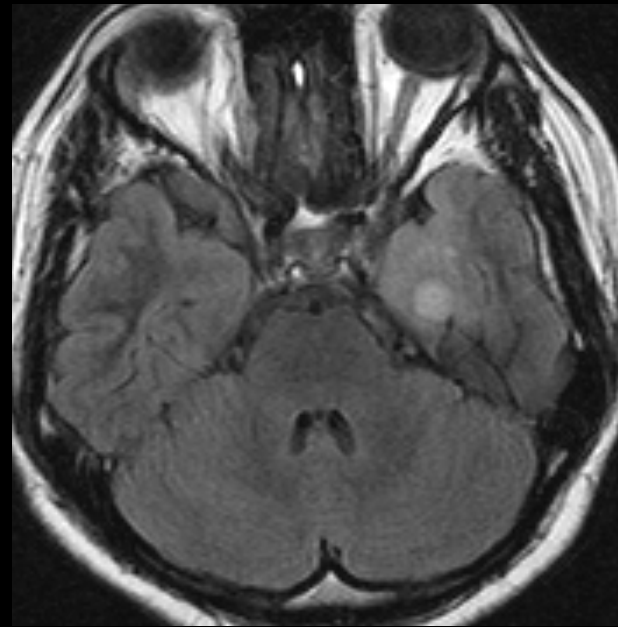
A 3-year-old girl with intractable seizure
(Her first seizure was at the age of 3 months.)

Ganglioglioma

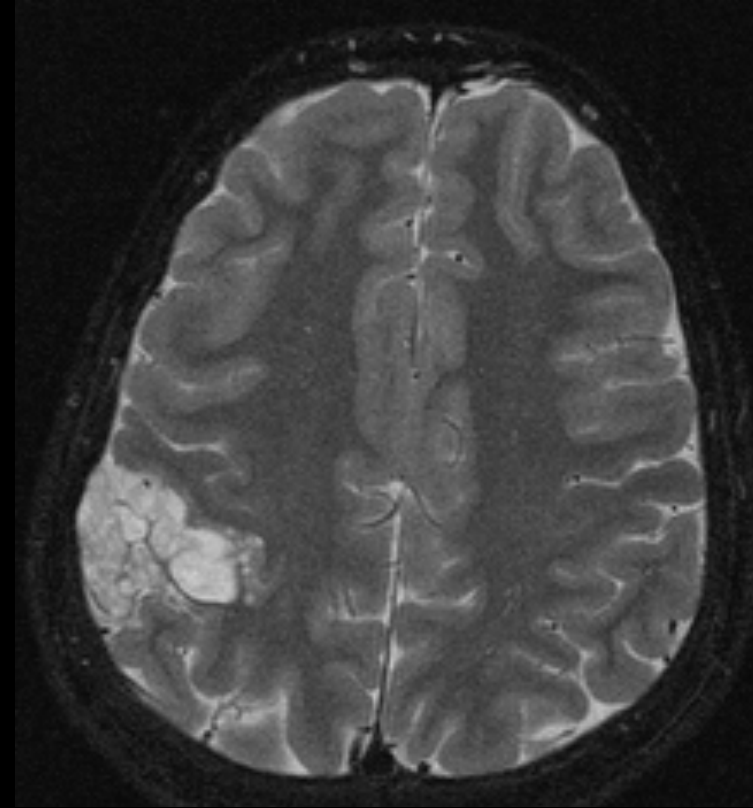
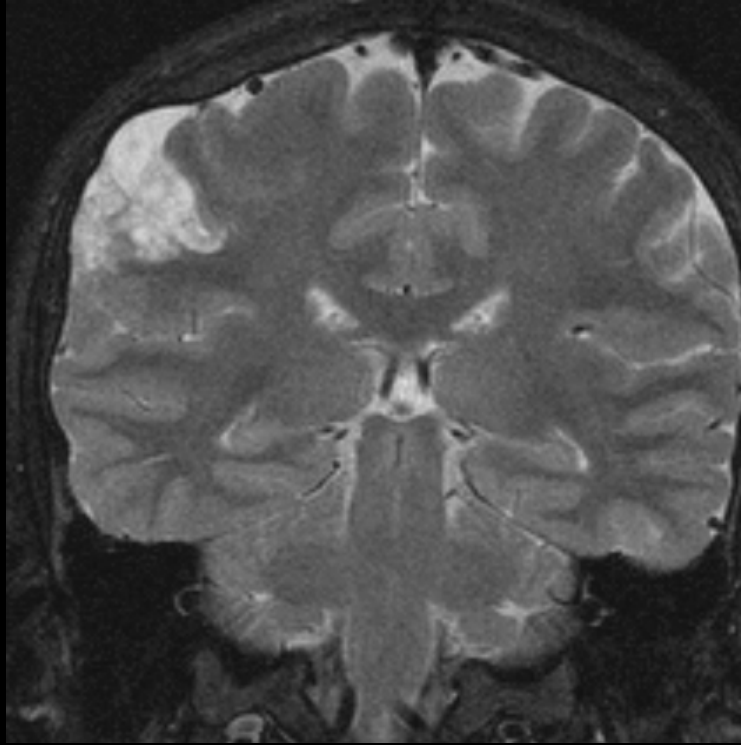


A 17-year-old female with complex partial seizure for 5 years

Pilocytic Astrocytoma

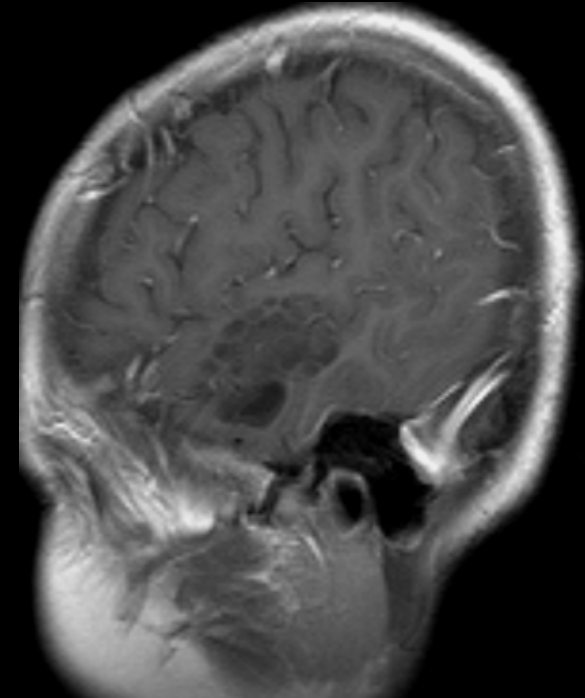
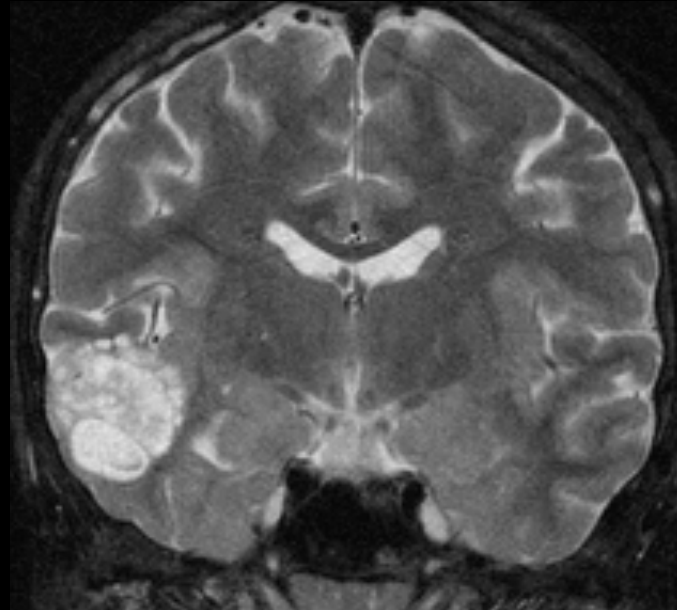
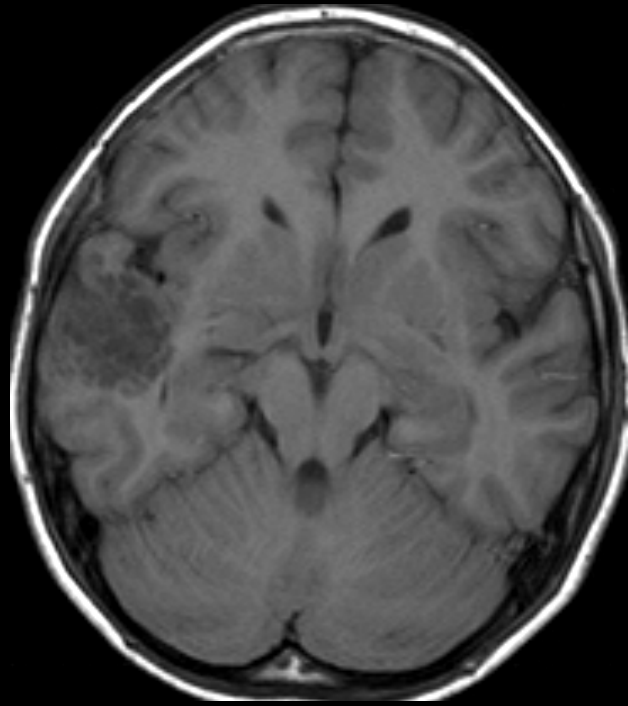


Dysembryoplastic Neuroepithelial Tumor (DNET)



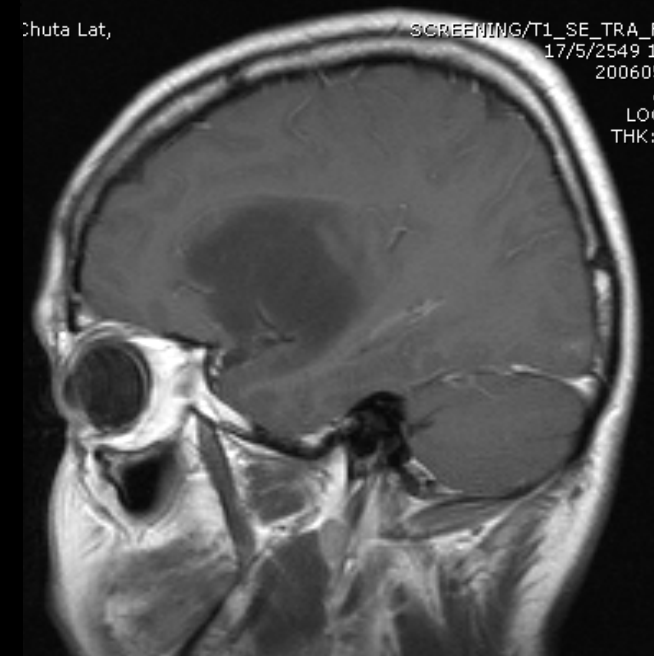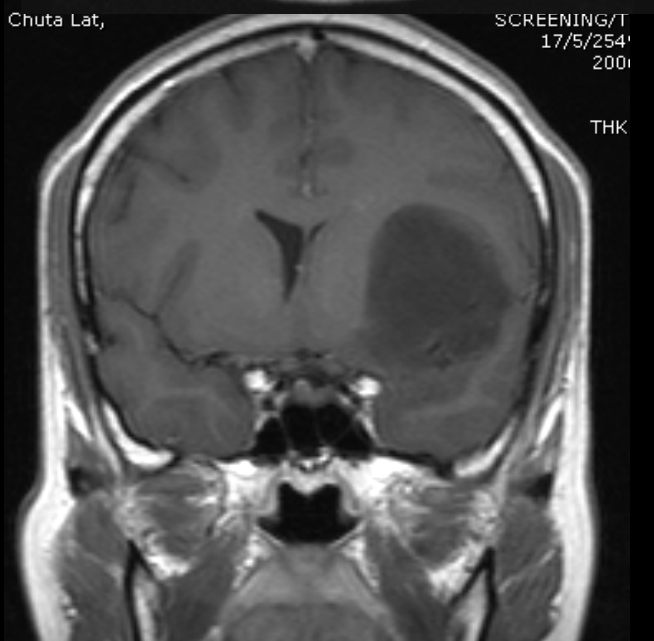
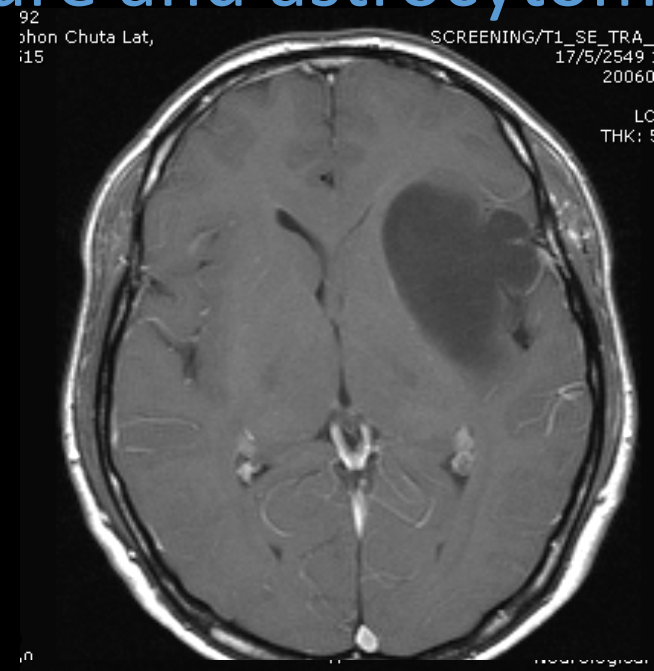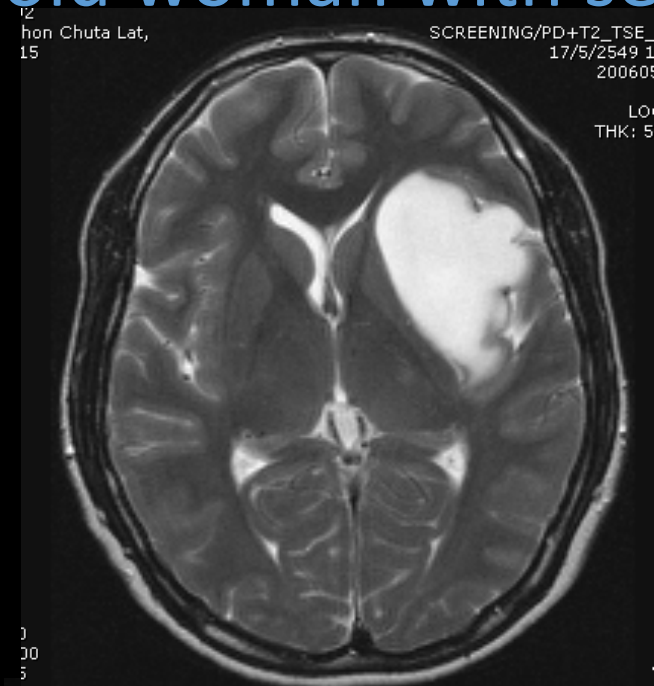
A 13-year-old boy with right-sided headache and left-sided numbness prior to generalized epilepsy

Dysembryoplastic Neuroepithelial Tumor (DNET)



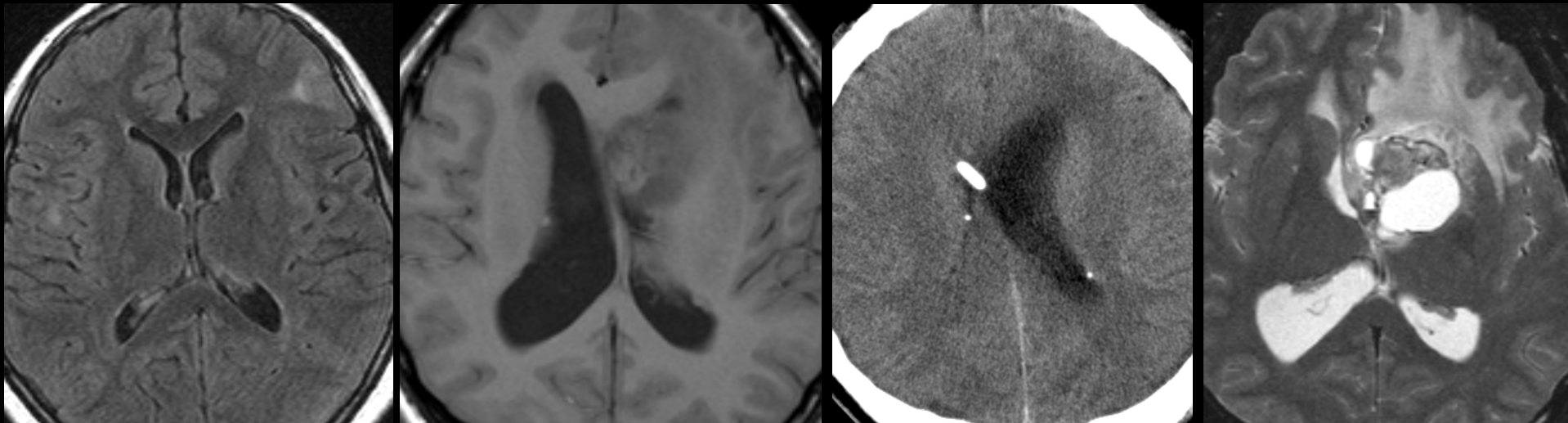
An 11 year-old boy with complex partial seizure for more than a year

A 34-year-old woman with seizure and astrocytoma, grade II

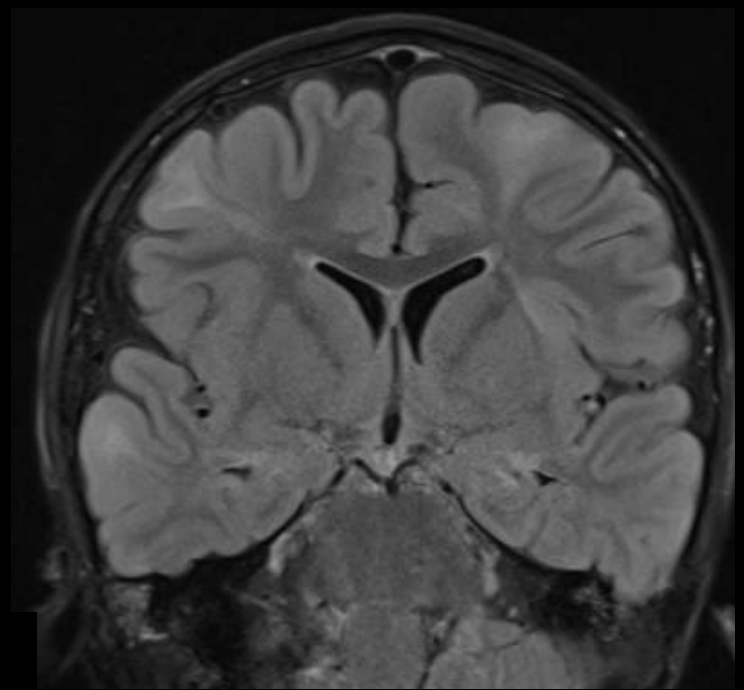
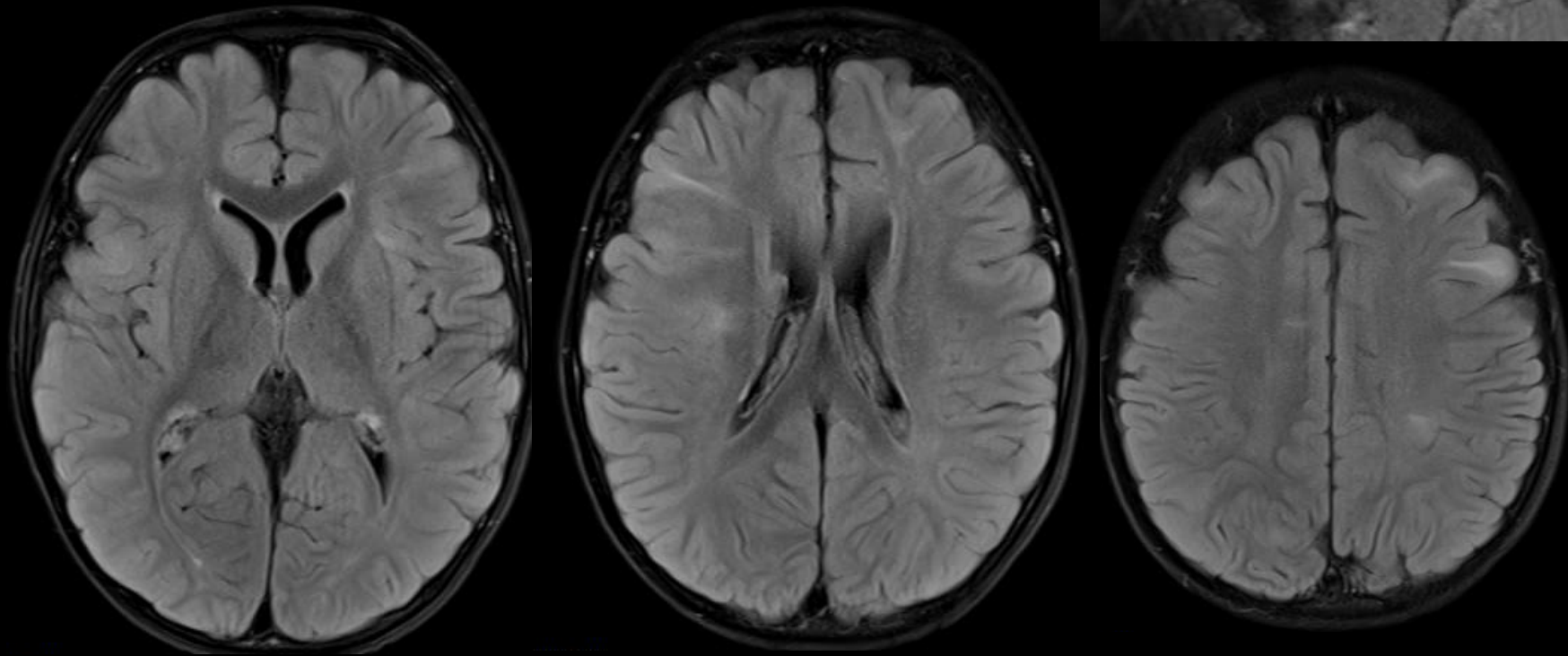


TUBEROUS SCLEROSIS

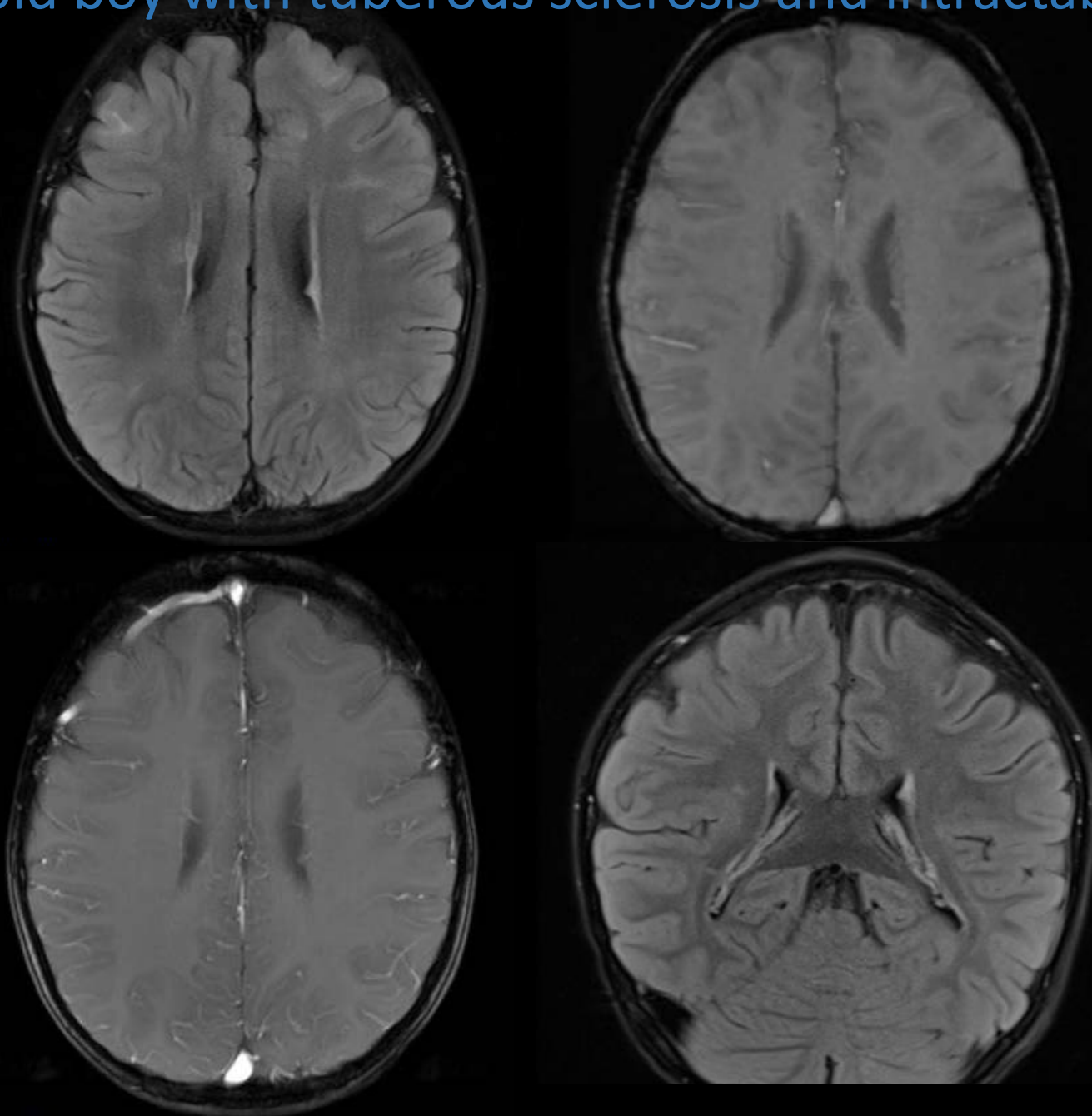
- Autosomal dominant genetic disease with hamartomas in multiple organs
- Clinical triad: mental retardation, epilepsy and adenoma sebaceum



A 5-year-old boy with tuberous sclerosis and intractable epilepsy



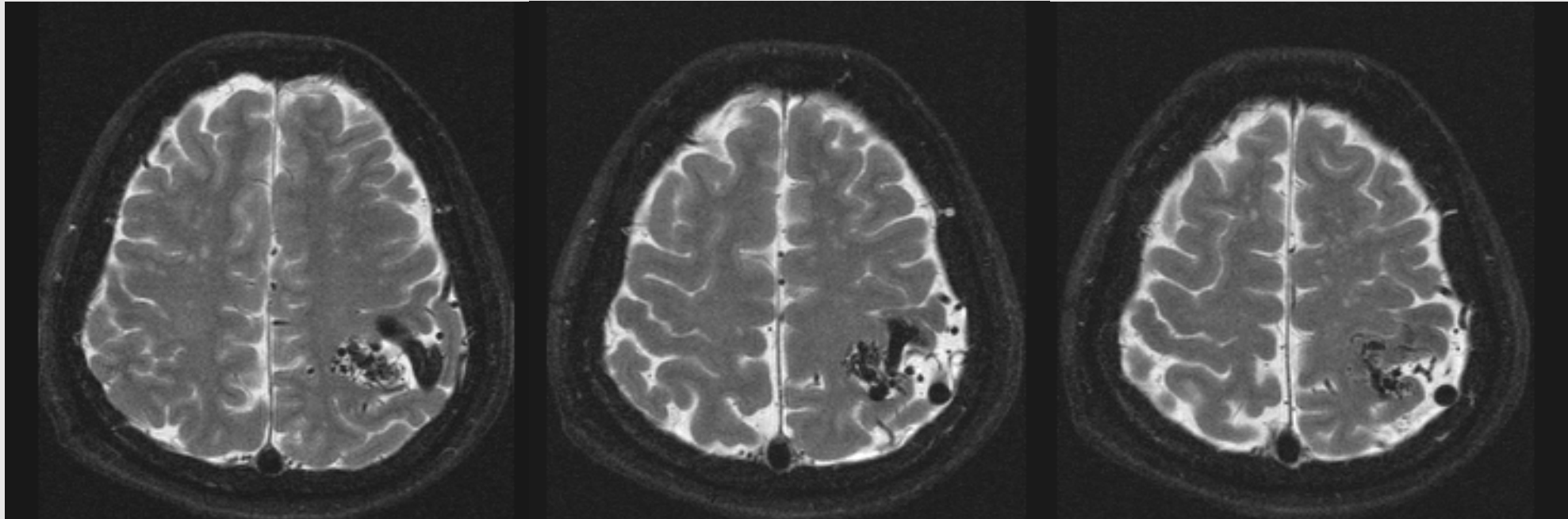
A 5-year-old boy with tuberous sclerosis and intractable epilepsy



VASCULAR MALFORMATION

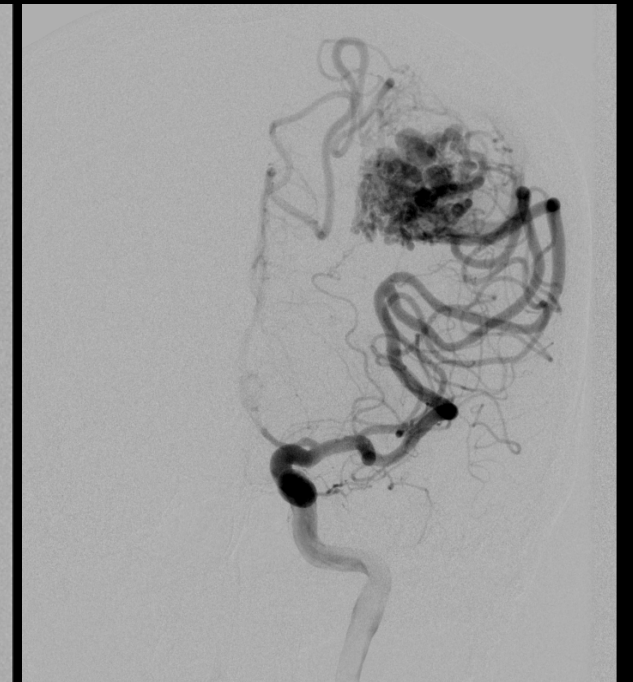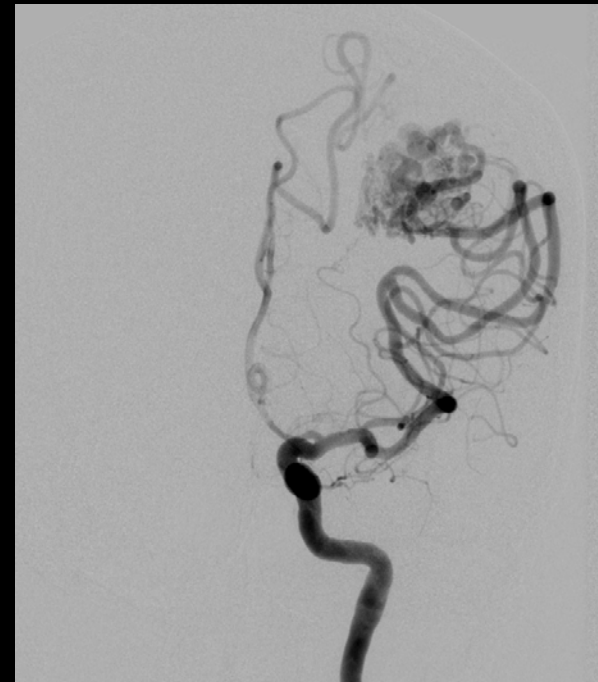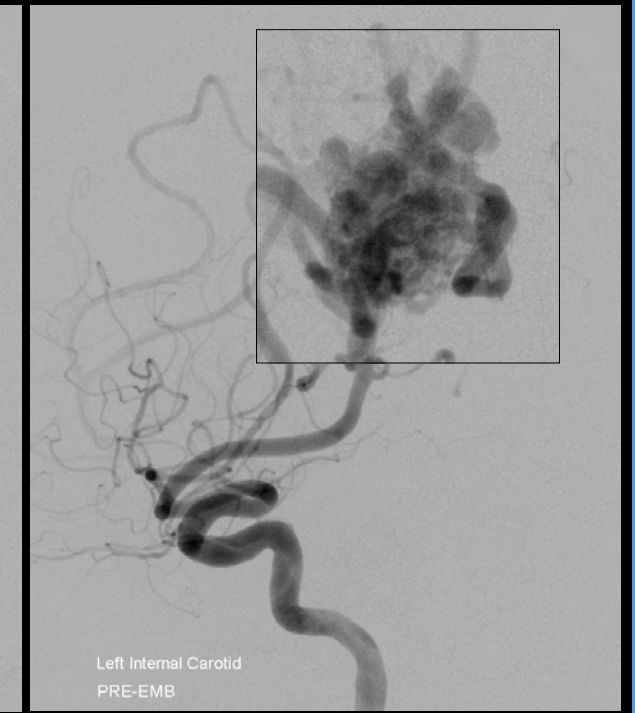
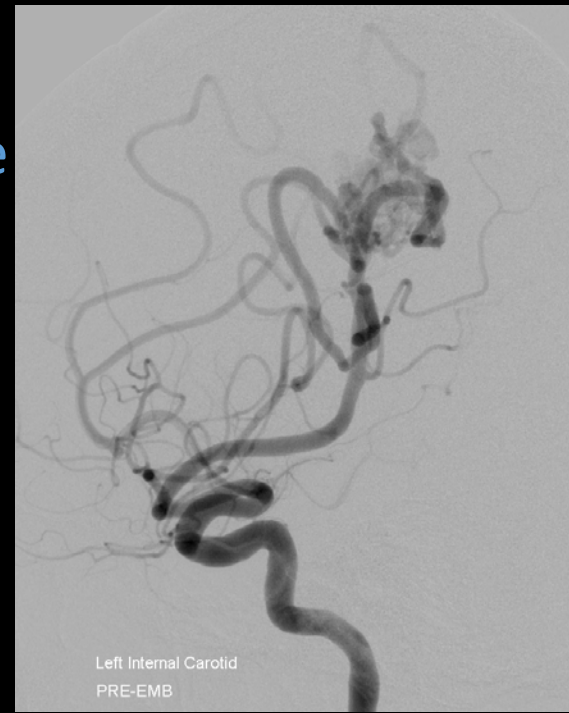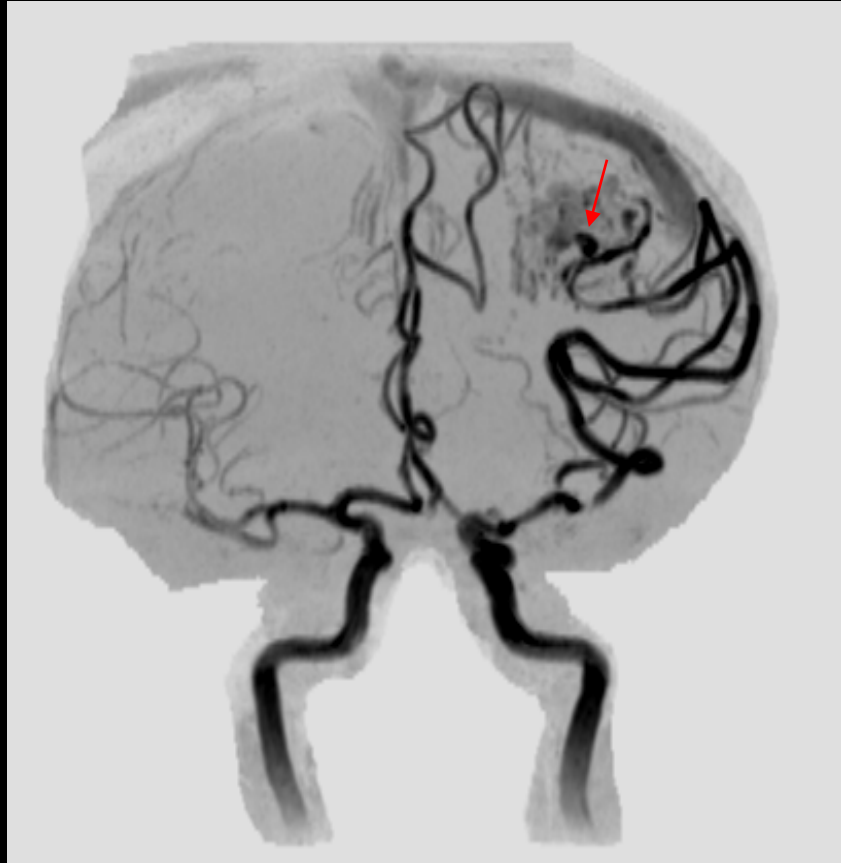
- Brain arteriovenous malformation (BAVM)
- Cavernous angioma or cavernoma: central hyperintensity due to haemoglobin products surrounded by a hypointense rim resulting from hemosiderin
- Most capillary telangiectasia and venous angiomas are clinically silent.

CORTICAL-SUBCORTICAL BRAIN AVM WITH SEIZURE

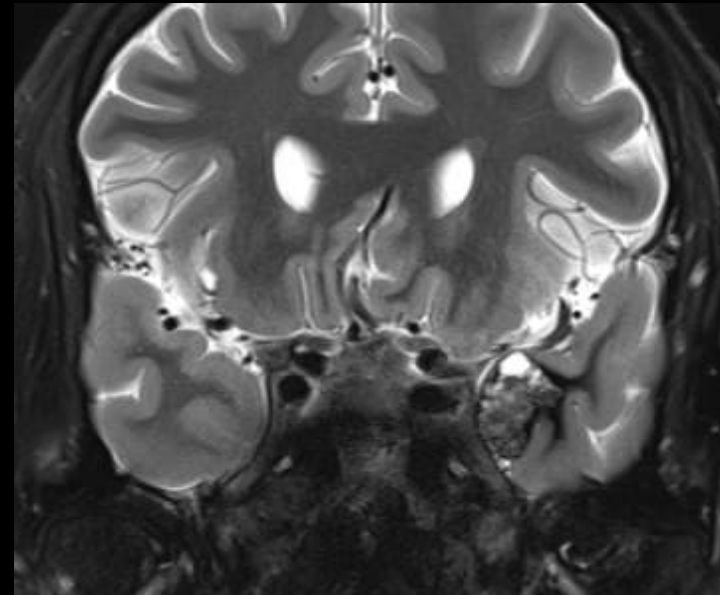
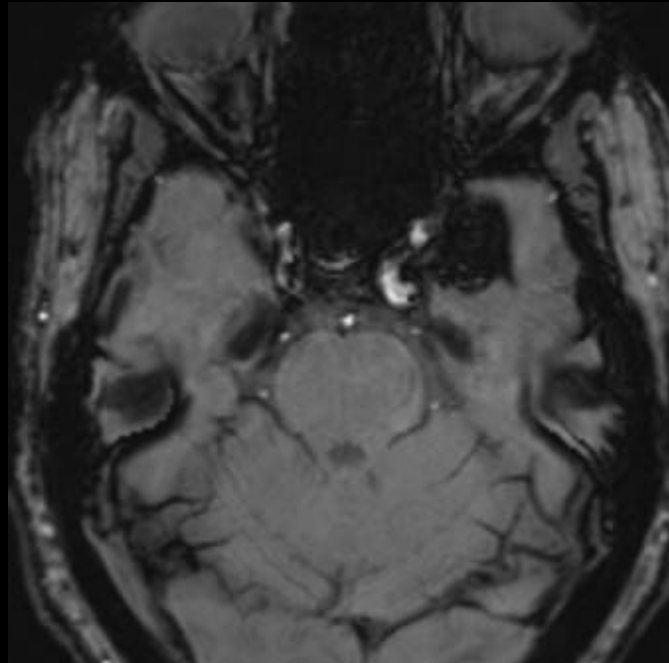
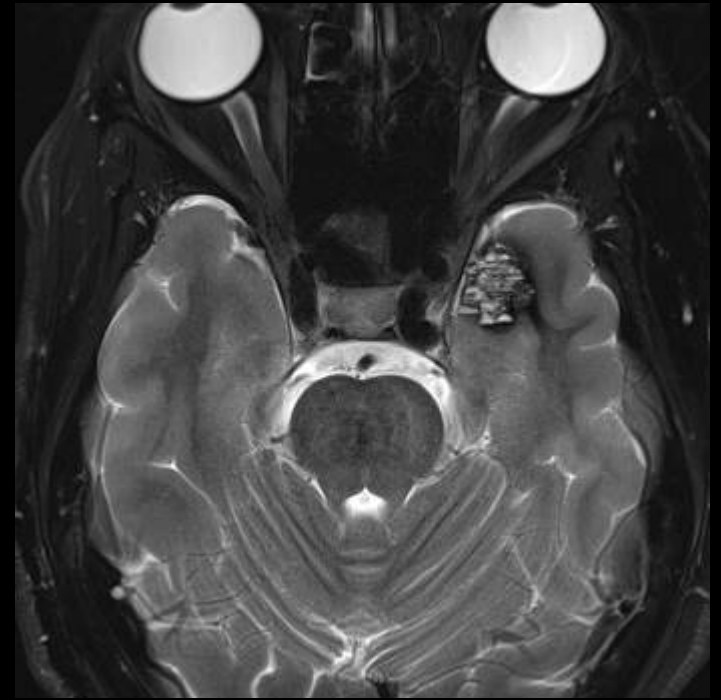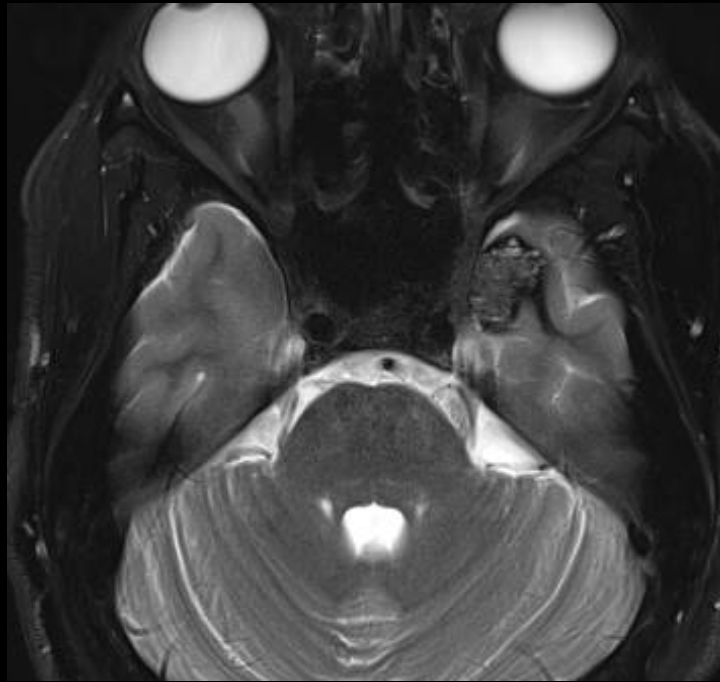


Seizure; a common clinical manifestation of intracranial AVMs (20-60%)
Often associated with the AVMs in the temporal and frontal regions

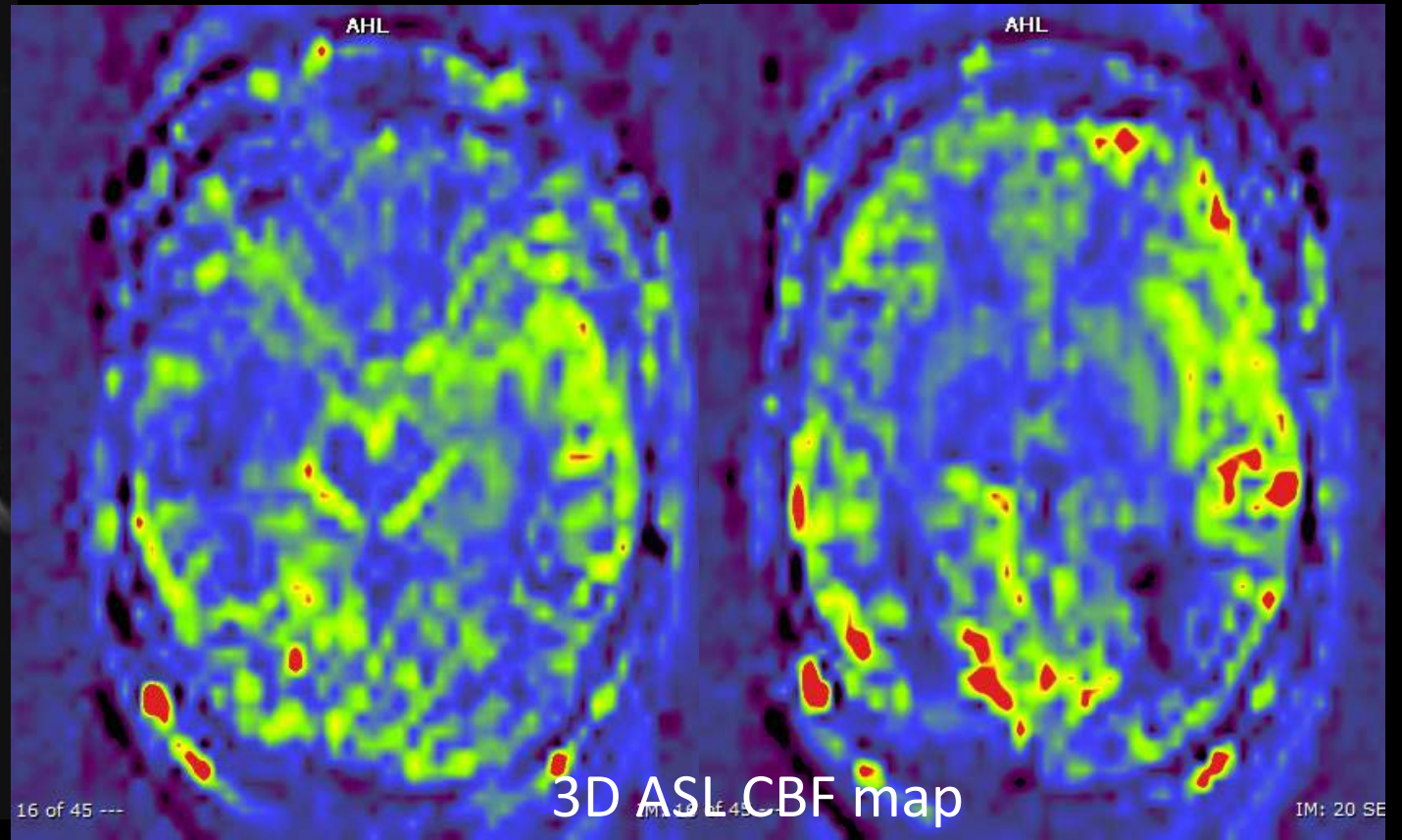
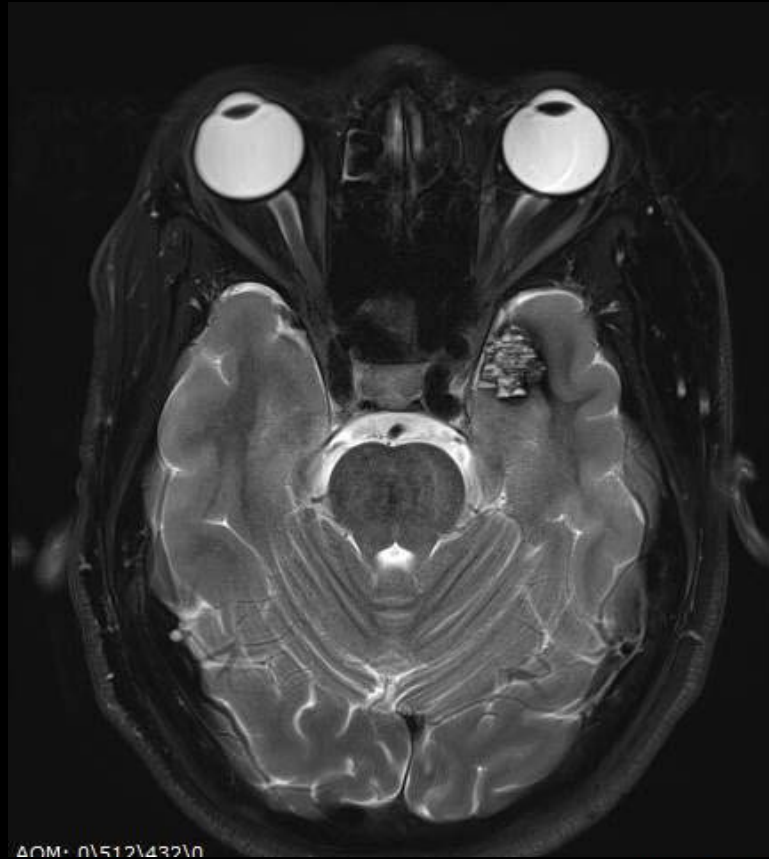3D TOF MRA brain and DSA images :
Cortical-subcortical AVM, It parietal lobe
* Intranidal aneurysm



A 35-year-old woman with (automotor) seizure and **cavernoma** at left temporal lobe



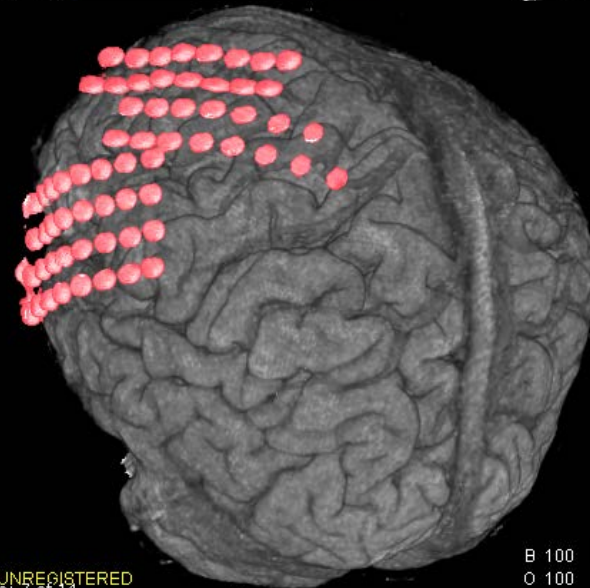
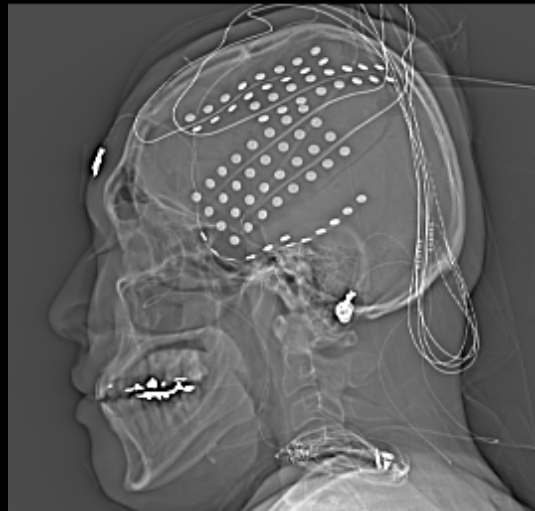
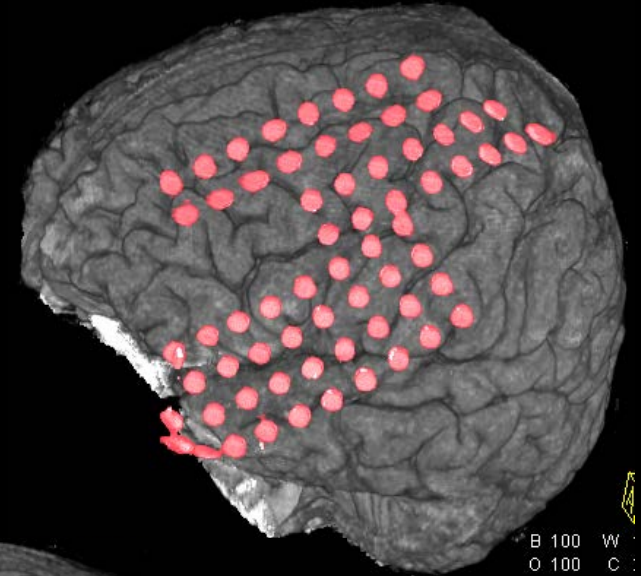
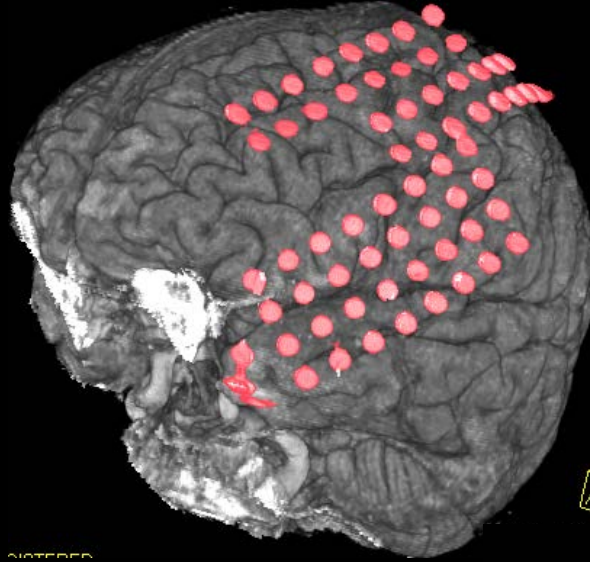
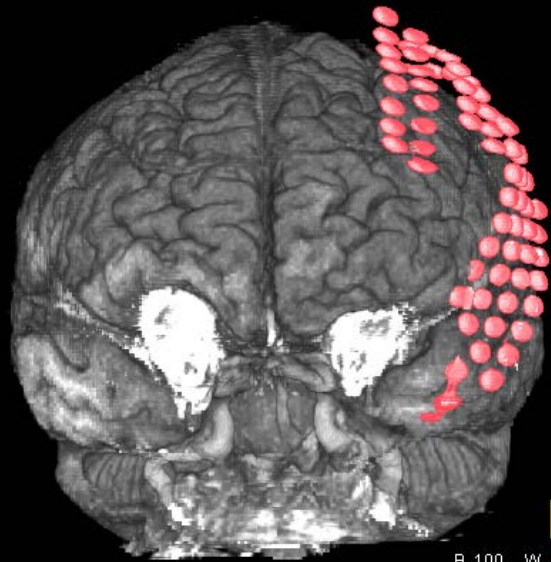
A 35-year-old woman with (automotor) seizure and cavernoma



ROLE OF NEUROIMAGING IN POSTOPERATIVE EVALUATION

- Determine the adequacy of resection, reasons for operative failure, complications
- Monitor tumor resections for recurrence, follow-up of other substrates
- Prognosticating the postoperative seizure control
- To identify any other previously unrecognized epileptogenic substrates at other location in the brain
- Intracranial EEG: verify the exact anatomic distribution of contacts.

SUBDURAL GRID IMPLANTATION FOR INTRACRANIAL EEG : MR AND CT FUSION



THANK YOU FOR YOUR ATTENTION

