

Introduction to Epilepsy Surgery

Teeradej Srikijsilakul, M.D.

*Department of Neurosurgery
Prasat Neurological Institute*

Goal of therapy in epilepsy

- No seizures
- No adverse events
- Improvement of quality of life

Randomized. Controlled trial of surgery for TLE

- In TLE, surgery is superior to prolonged medical therapy
- Seizure free, 58% surgery group vs. 8% medical group
($p < 0.001$)

Indication for epilepsy surgery

- Drug-resistant epilepsy (intractable, medically refractory)
 - “Failure of adequate trials of two tolerated and appropriately chosen and used antiepileptic medications to achieve sustained seizure freedom”
- Refer patients early to specialized epilepsy center to maximized their benefit for surgery

Type of Epilepsy Surgery (Therapeutic)

- Resective Surgery
- Disconnective Surgery
- Thermocoagulation
- Radiosurgery
- Neurostimulation

Resective surgery

- Lesionectomy
- Topectomy, Gyrectomy, Corticectomy
- Lobectomy
- Multilobar resection
- Hemispherectomy

Disconnective surgery

- Hippocampal transection
- Hypothalamic hamartoma disconnection
- Corpus callosotomy
- Multiple subpial transection

Thermocoagulation

- Thermal
- Laser ablation
- Hippocampal sclerosis
- Hypothalamic hamartoma
- Heterotopia

Radiosurgery

- Gamma knife radiosurgery
- LINAC
- Hippocampal sclerosis
- Hypothalamic hamartoma
- Corpus callosotomy
- Cavernoma, AVM

Brain stimulation

- CNS stimulation
 - Cerebellum
 - Deep brain structures: CM-Pf, STN, ATN
 - Hippocampal stimulation
 - Direct stimulation of epileptogenic zone (RNS)
- PNS stimulation
 - VNS
 - Trigeminal nerve stimulation

Others

- Radiosurgery
- Thermocoagulation

Locations

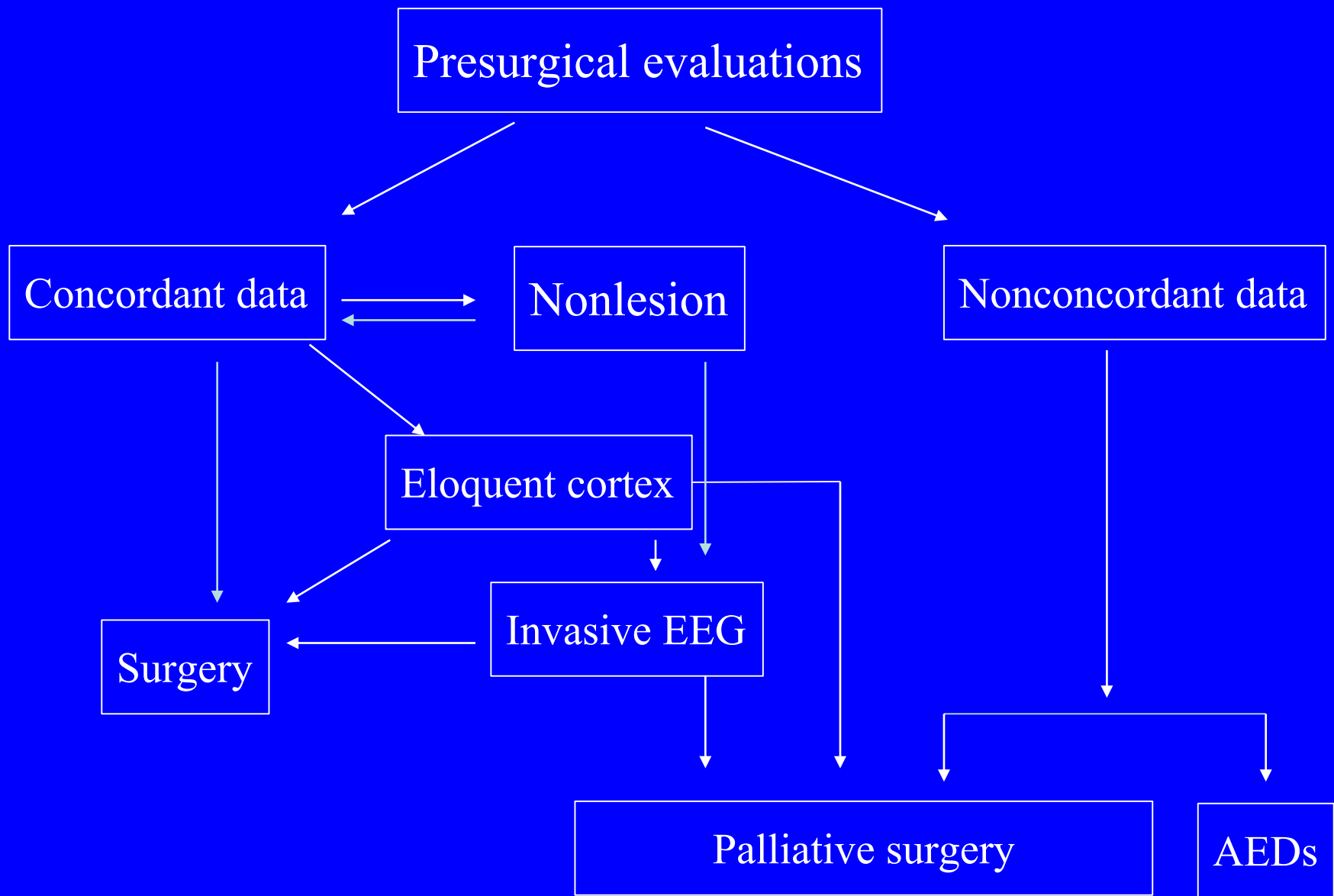
- Temporal
- Extratemporal
- Multi-lobar
- Hemispheric

Principal considerations

- Epileptogenic zone
- Symptomatogenic zone
- Irritative zone
- Ictal onset zone
- Epileptogenic lesion
- Functional deficit zone

Presurgical evaluations

- H&P
- Routine EEG, 24-hour video EEG, MRI
- Ictal SPECT, PET, fMRI
- Neuropsychological test
- WADA test
- Invasive monitoring
- Intraop EcoG



Type of surgery

- Adults

- Most common

- Temporal lobe resection

- Pediatrics

- Most common

- Extratemporal
- Multilobar
- Hemispherectomy

Temporal lobe surgery

Etiologies

- Hippocampal sclerosis
- Tumors
 - Ganglioglioma, DNET, Glioma
- Cortical dysplasia
- Vascular malformations
- Trauma
- Inflammatory/ infectious
- Non-specific lesions

Anatomy

- Lateral temporal lobe
 - Superior, middle, inferior temporal lobe
- Inferior temporal lobe
 - Inferior temporal, fusiform, parahippocampus
- Mesial temporal lobe
 - Hippocampus, parahippocampus, amygdala

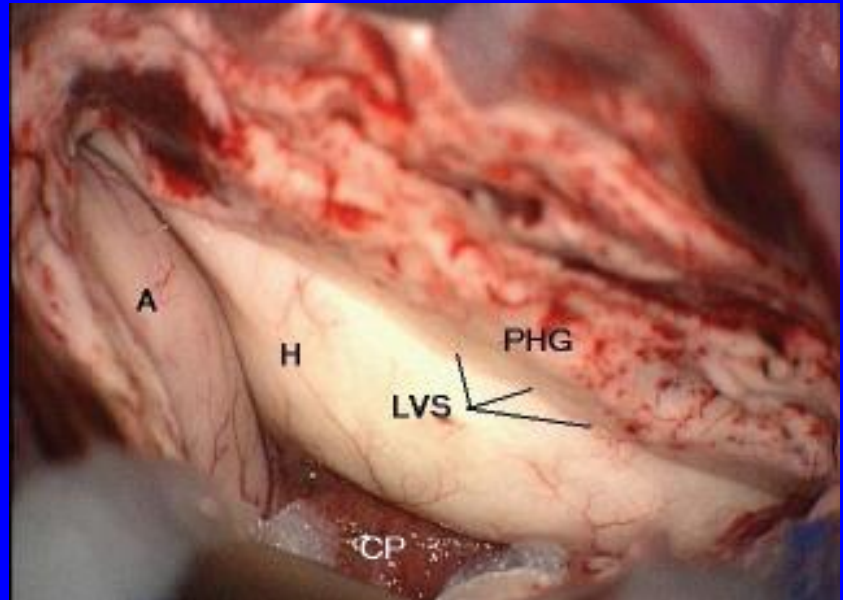
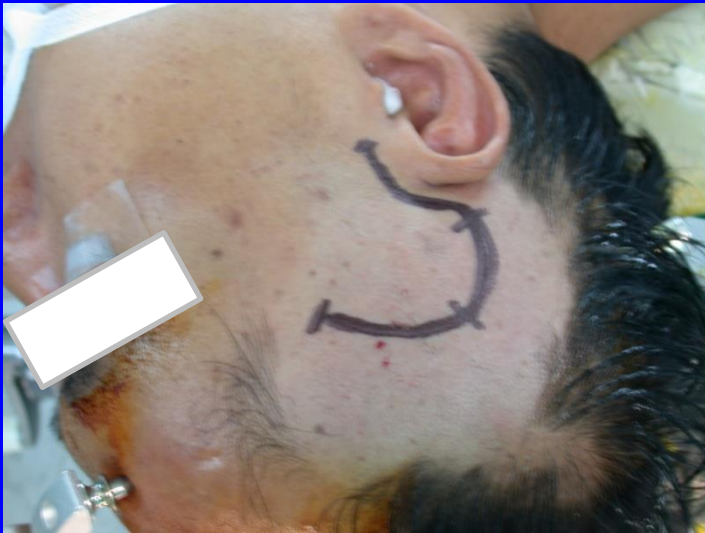Temporal lobe resections

- Corticoamygdalohippocampectomy (standard temporal lobectomy)
- Amygdalohippocampectomy (Selective)
- Neocortical resection
- Lesion resection

Standard temporal lobectomy

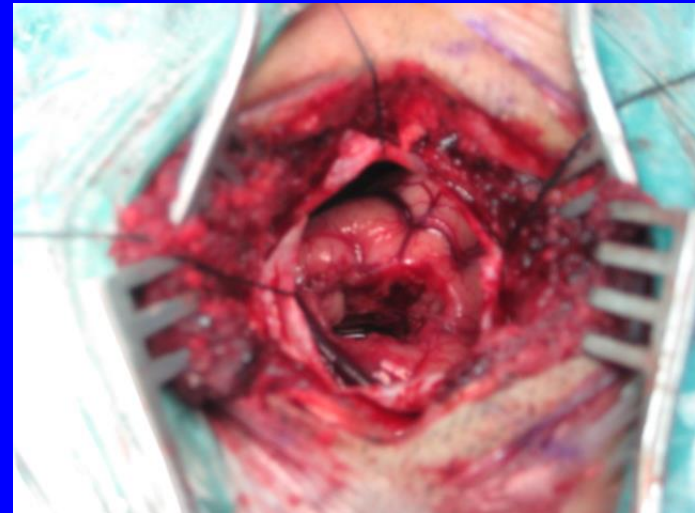
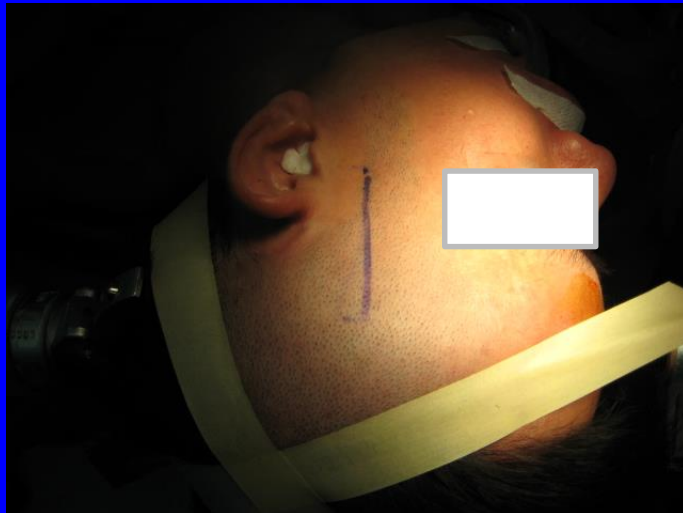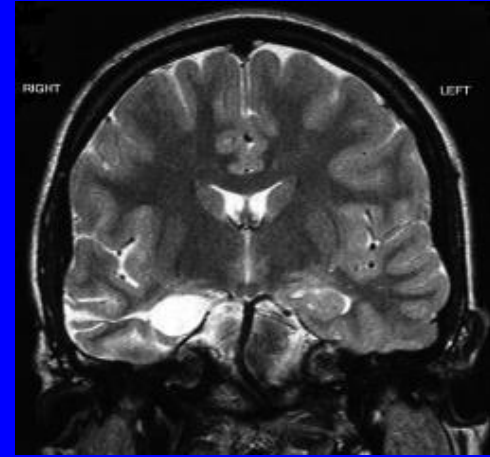
- Anterior temporal lobectomy (ATL)
- Corticoamygdalohippocampectomy
- Anterior one-third temporal lobectomy

Anterior temporal lobectomy



Selective amygdalohippocampectomy (SAH)

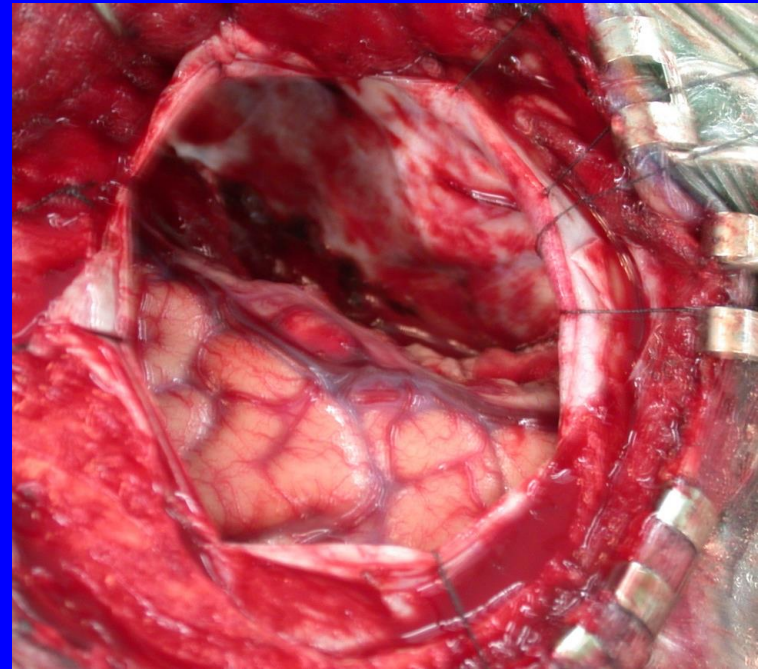
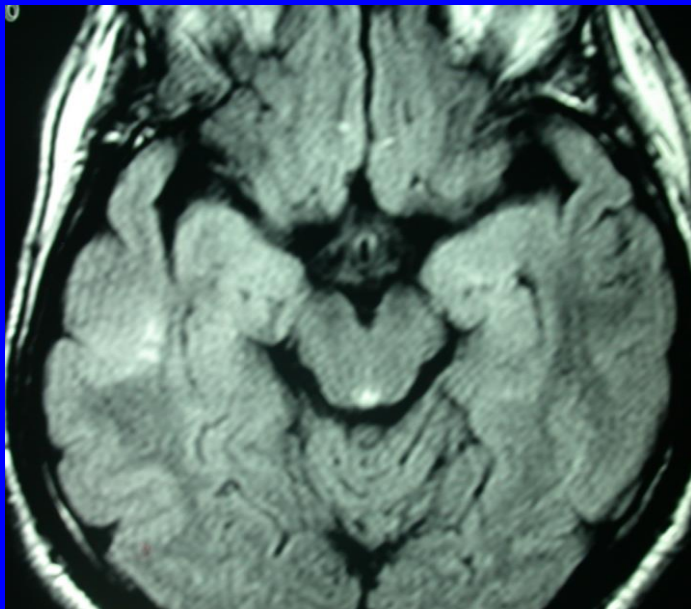
- Transylvian AH
- Transcortical AH
- Subtemporal AH



Tailored resection

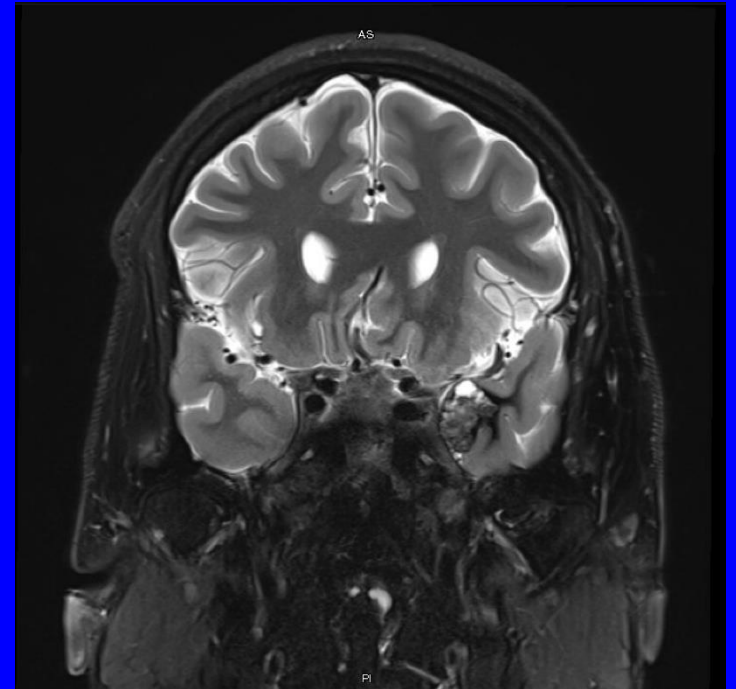
- Temporal lobectomy with intraoperative ECoG (awake?)

Focal cortical dysplasia (FCD)



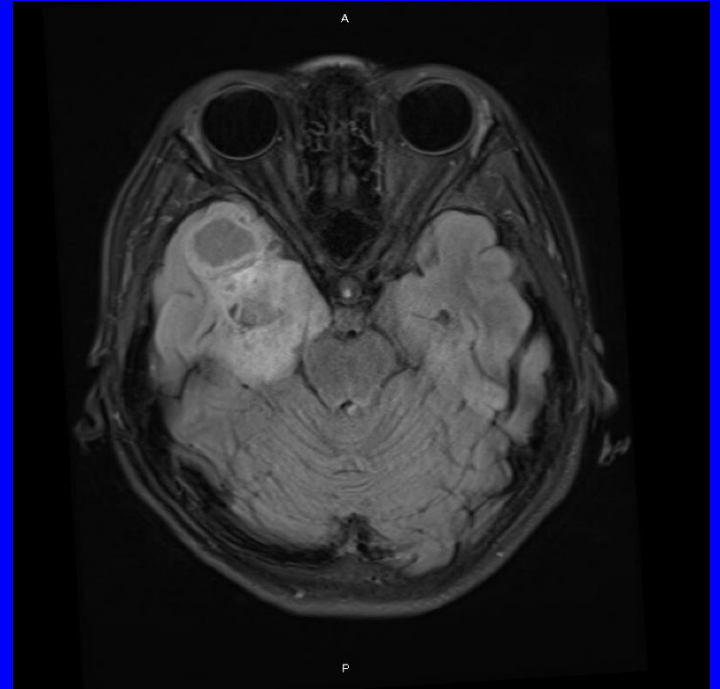
Cavernoma

- Lesionectomy
- Corticectomy \pm Intraop ECoG
- \pm Mesial structures

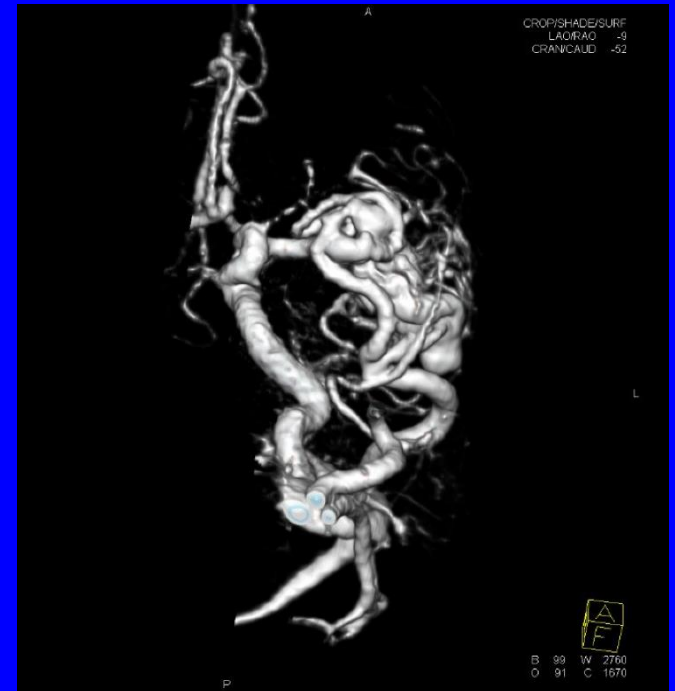
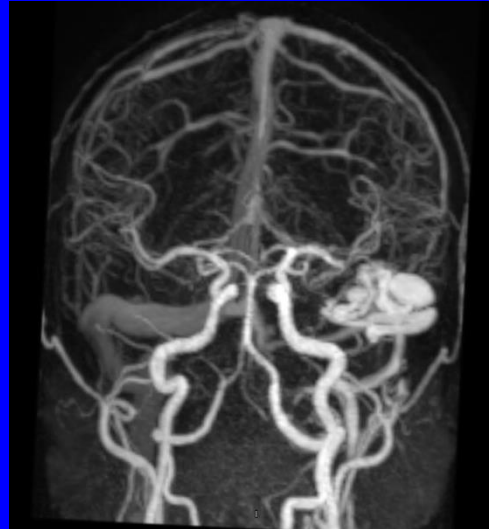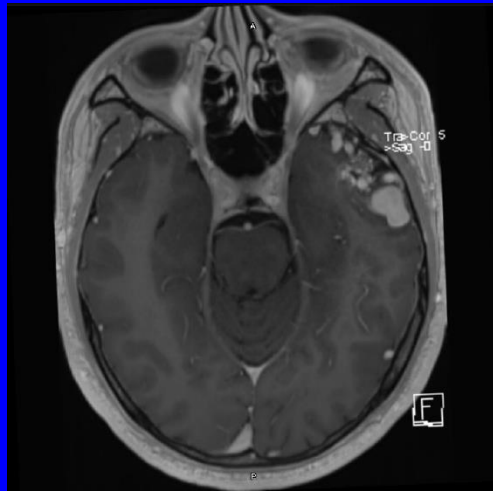


Tumor

- Lesionectomy
- ± Mesial structures
- ± Intraop ECoG



AVM



Complications (temporal lobectomy)

- Surgical complications
 - Hemiparesis
 - Visual field defect (superior quadrantanopia)
 - CN III, IV, VII
 - Infection
 - Intracranial hemorrhage

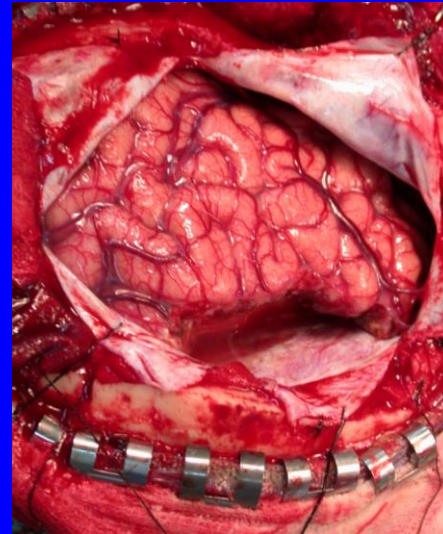
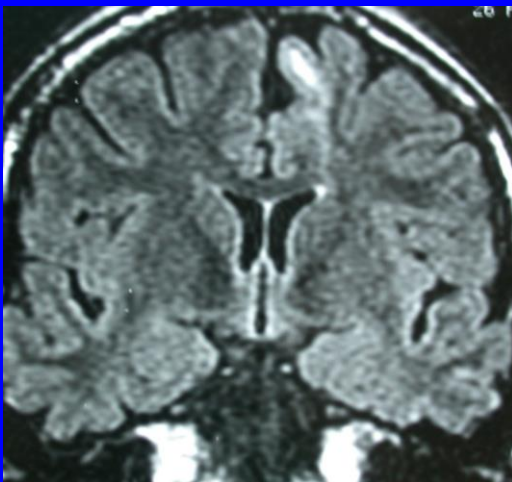
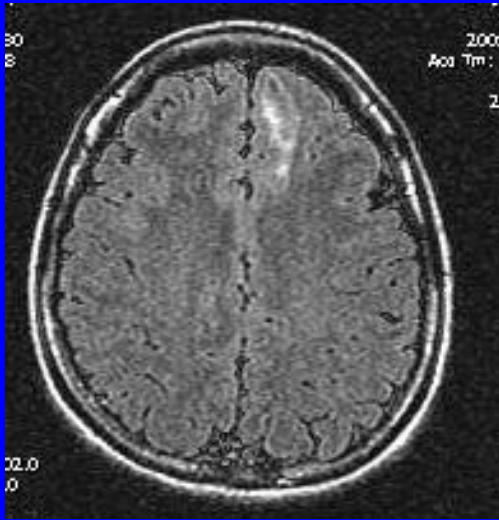
Complications (temporal lobectomy)

- Neurobehavioural complications
 - Memory
 - Cognitive
 - Language
 - Psychiatric
 - Psychosocial

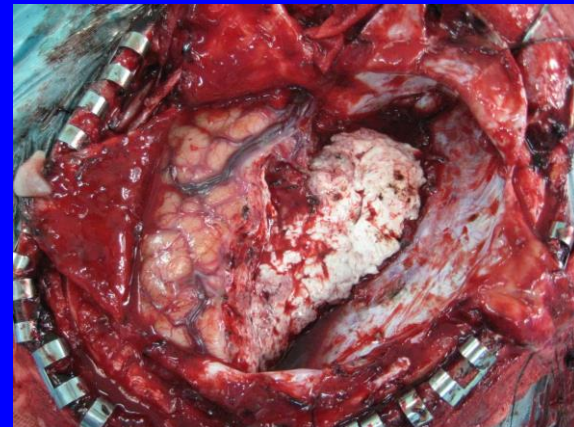
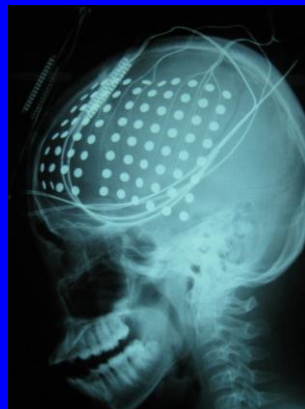
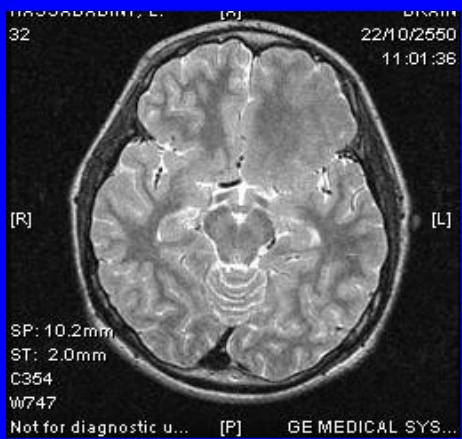
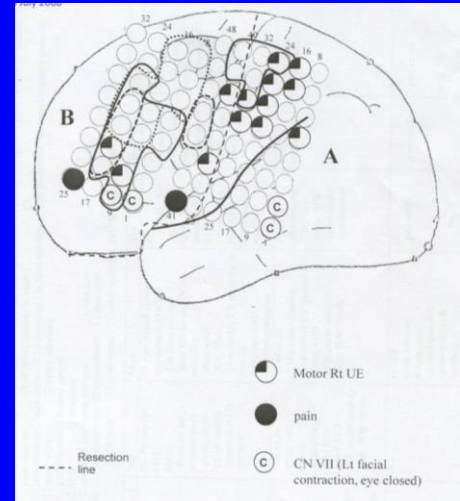
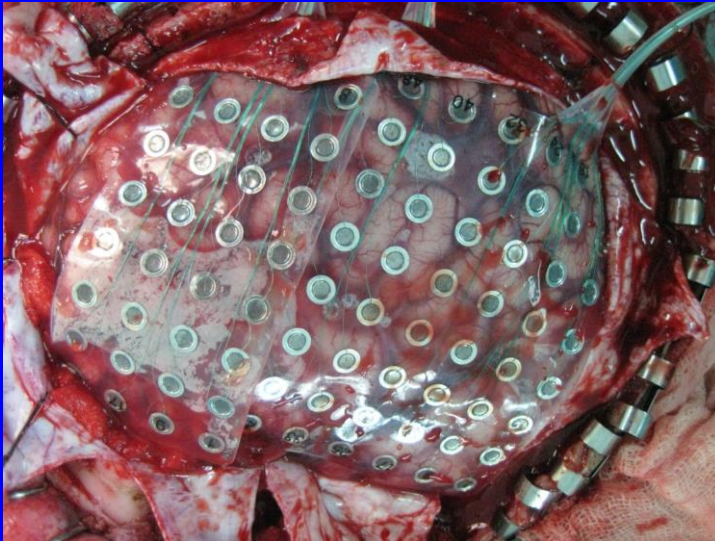
Extratemporal resections

- CD
- Tumor
- Cavernoma
- Nonlesional
- Frontal
- Parietal
- Occipital

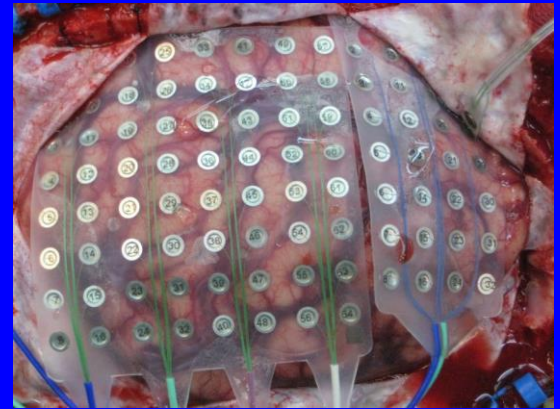
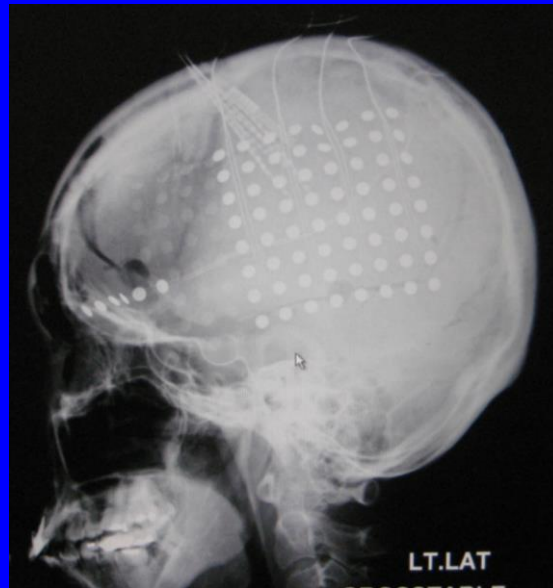
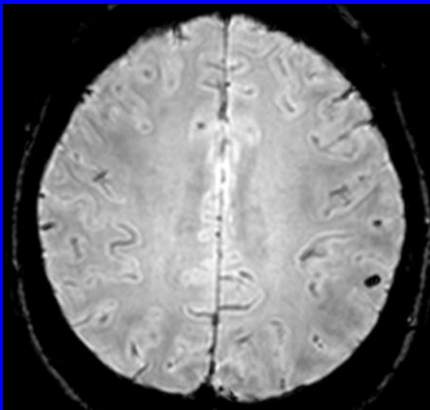
Left frontal FCD



Left frontal CD



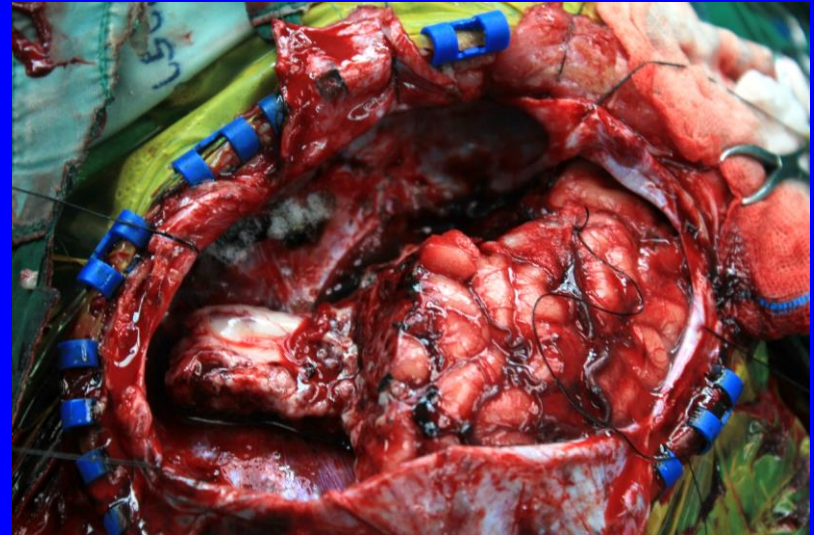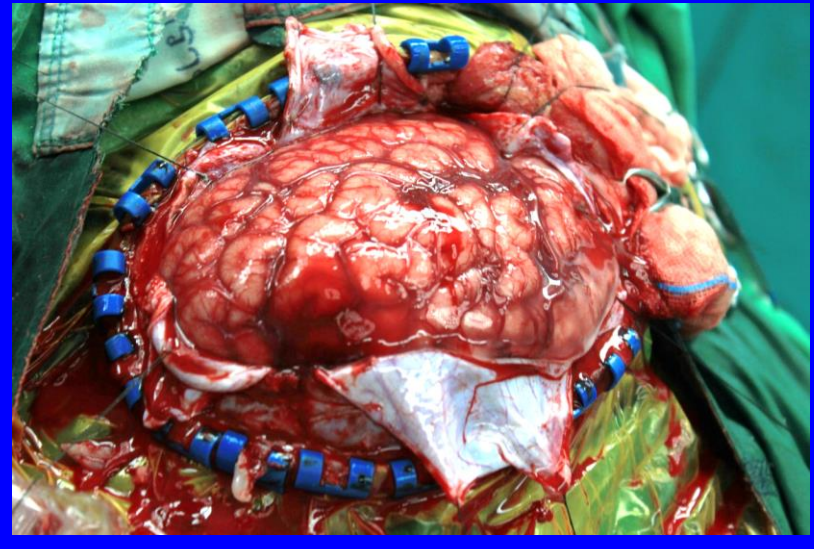
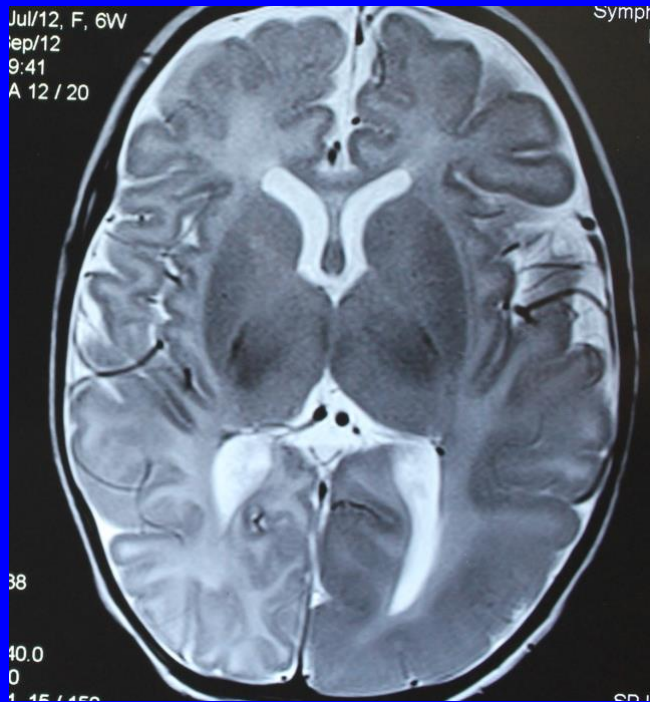
FLE (nonlesional)



Multilobar resections

- Cortical dysplasia
- Encephalomalacia
- Sturge-Weber syndrome
- F-T
- T-P-O

L) T-P-O resection (CD)



Hemispherectomy

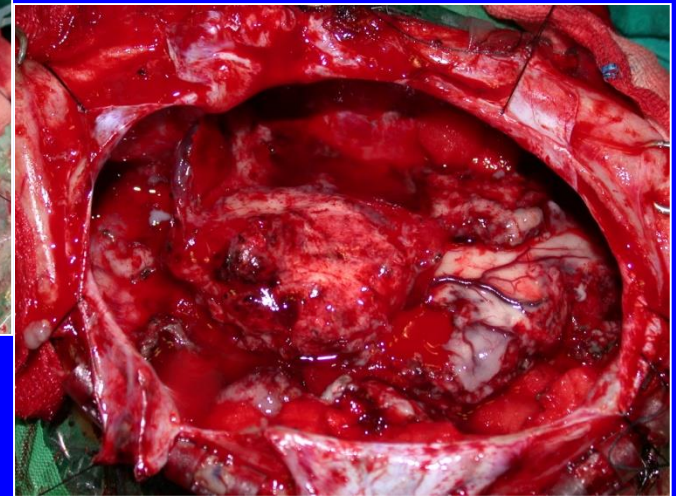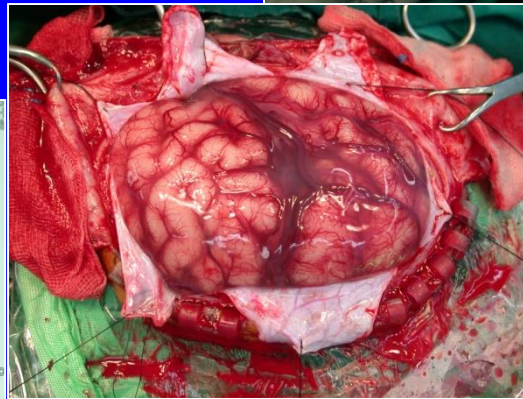
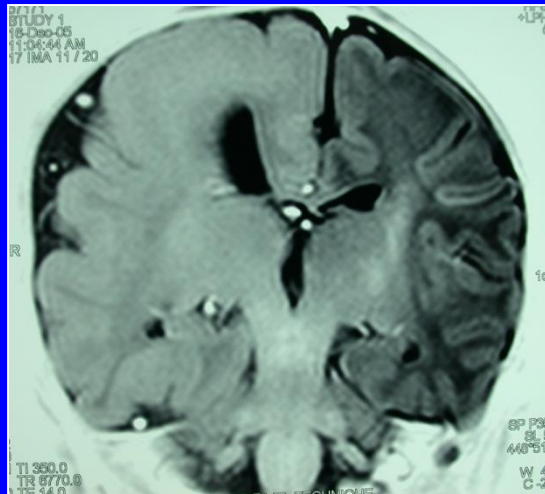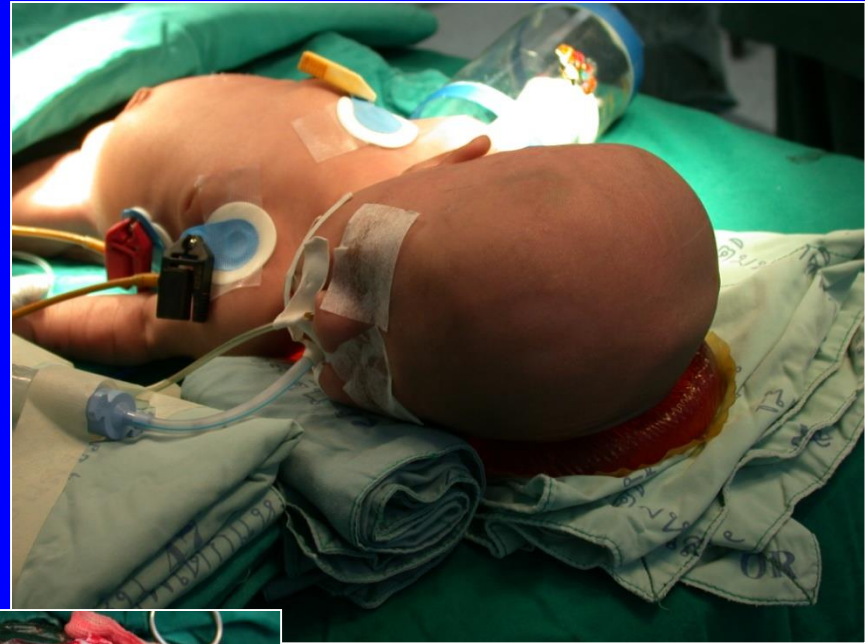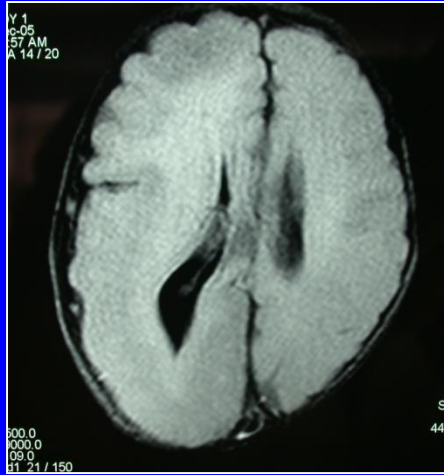
Hemispherectomy

- Indications:
 - Rasmussen's encephalitis
 - Sturge-Weber syndrome
 - Hemimegalencephaly
 - Infantile hemiplegic epilepsy

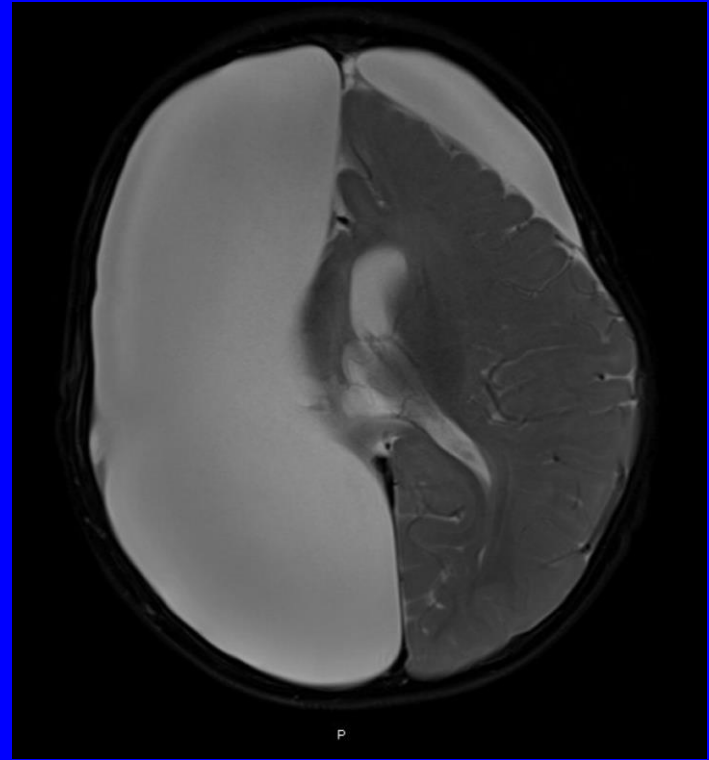
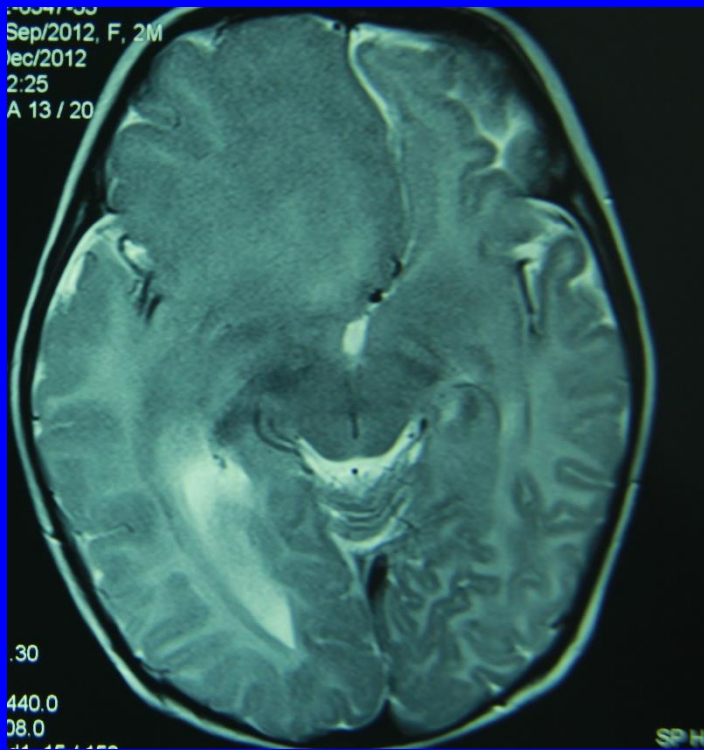
Hemispheric Surgical Procedures

- Anatomic hemispherectomy
- Modified anatomic hemispherectomy
- Functional hemispherectomy
- Hemidecortication

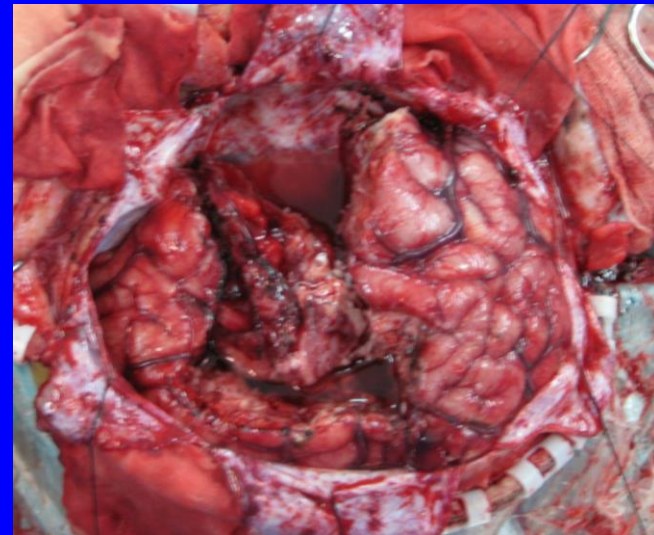
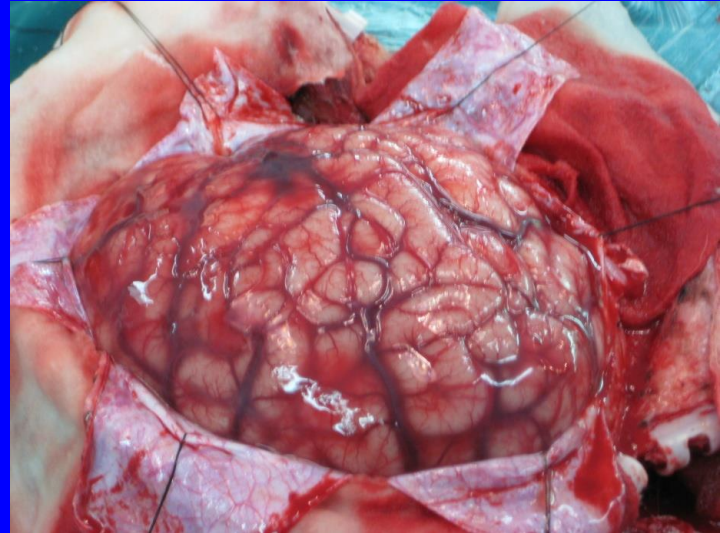
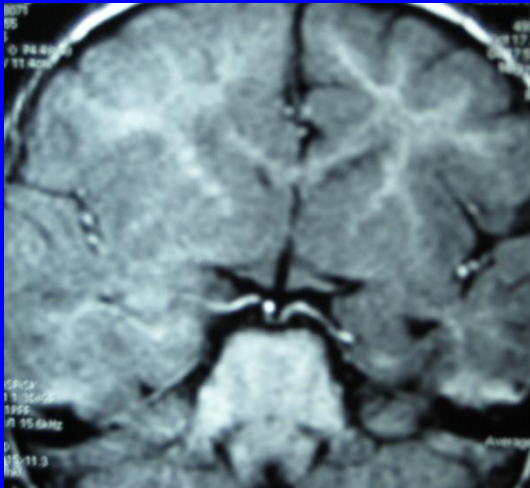
Anatomical hemispherectomy



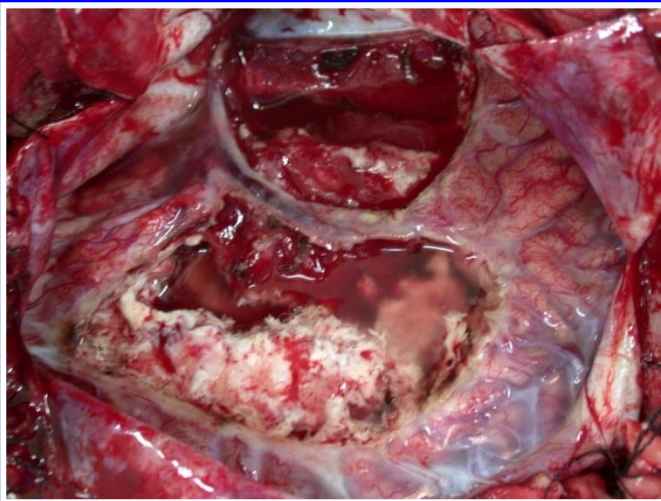
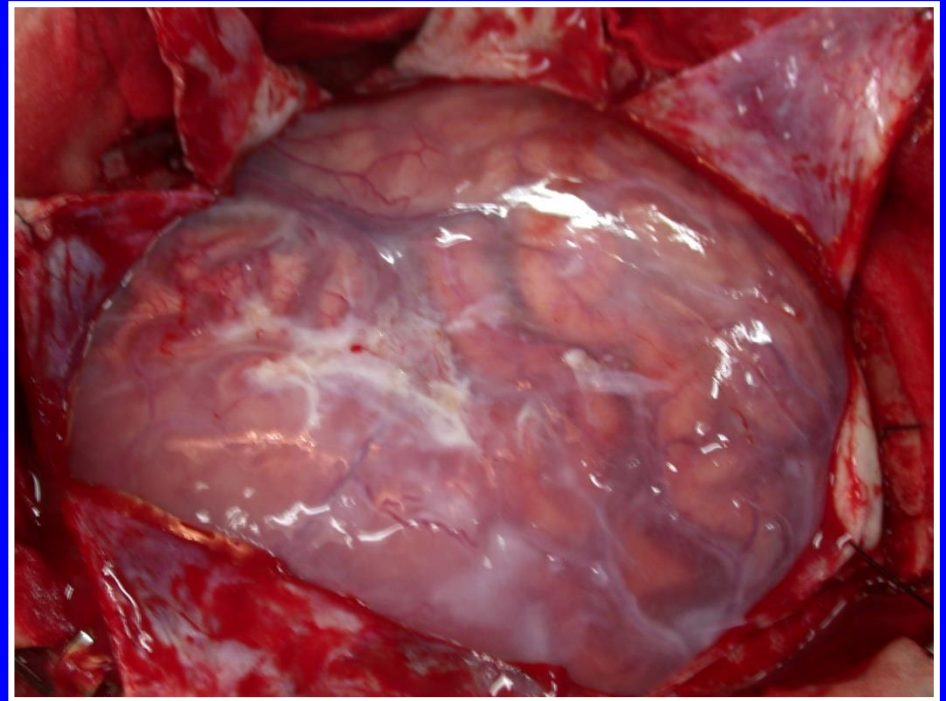
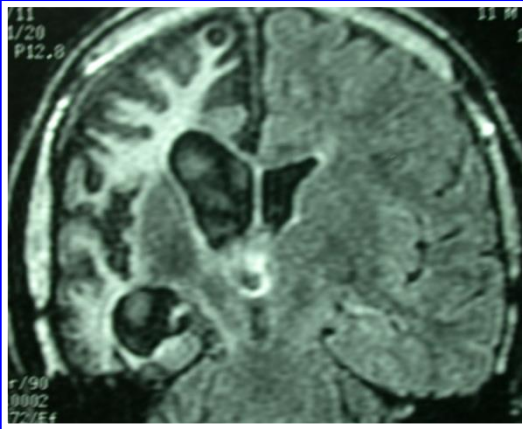
Anatomical Hemispherectomy



Functional hemispherectomy



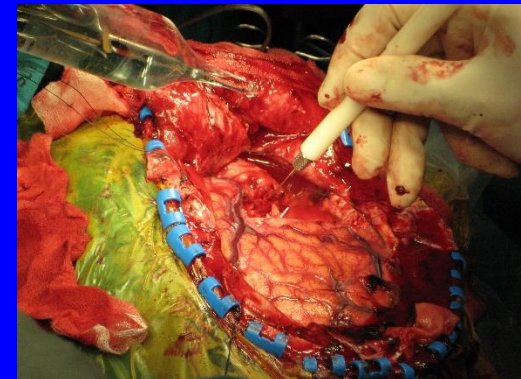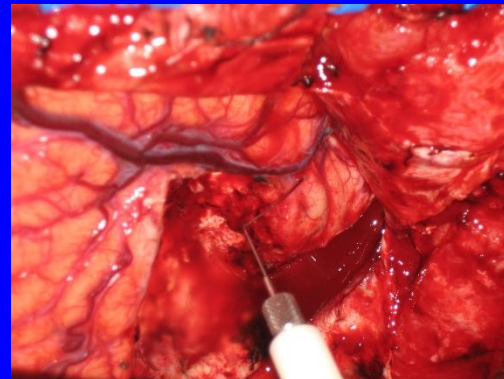
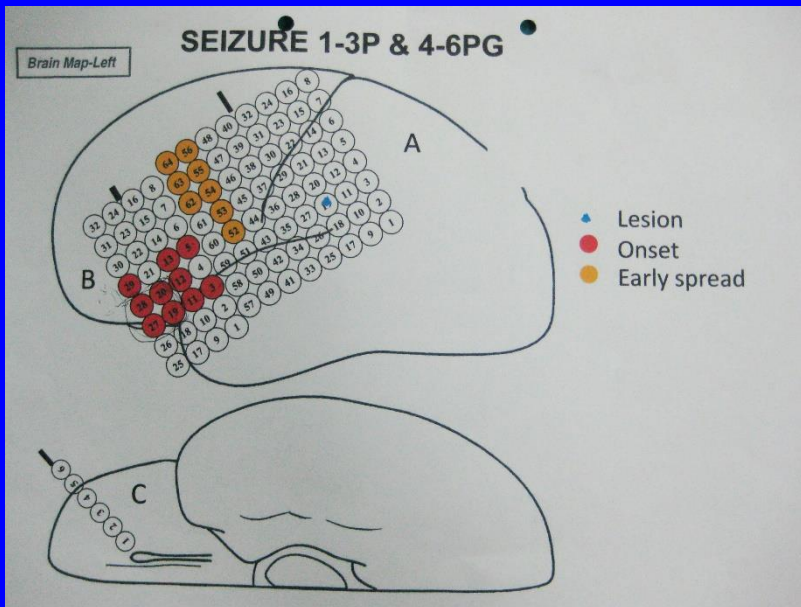
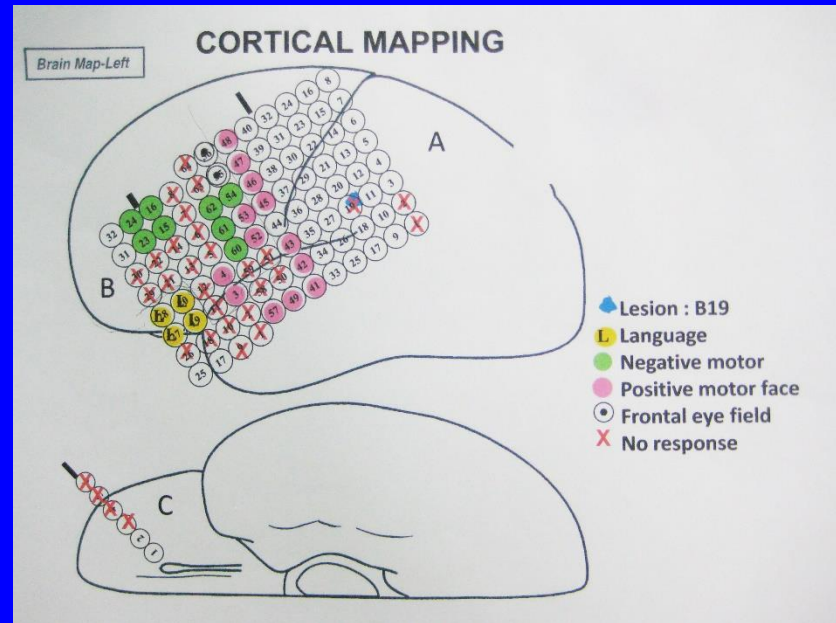
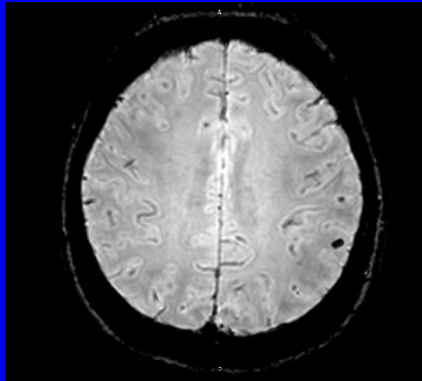
Rasmussen's encephalitis



Complications (Hemispherectomy)

- Bleeding
- Hydrocephalus
- Postoperative fever
- Superficial hemosiderosis

Multiple subpial transection

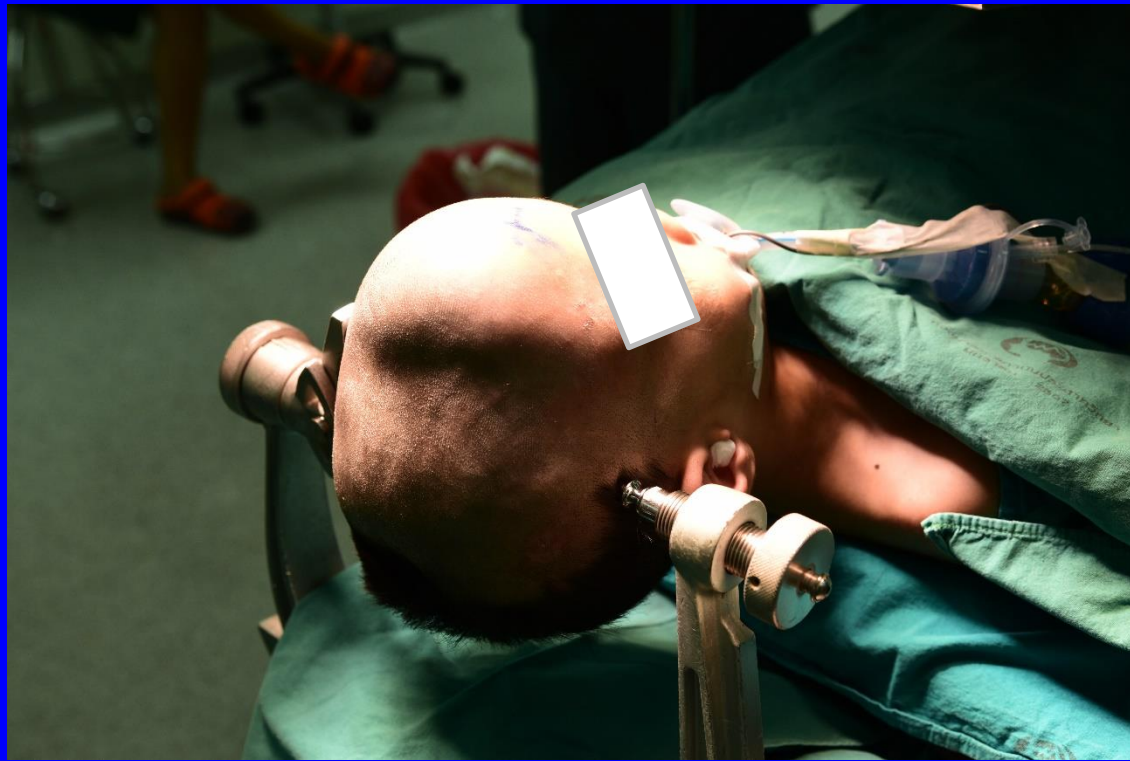

Corpus callosotomy

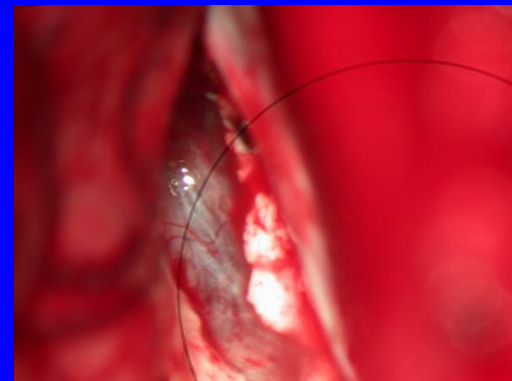
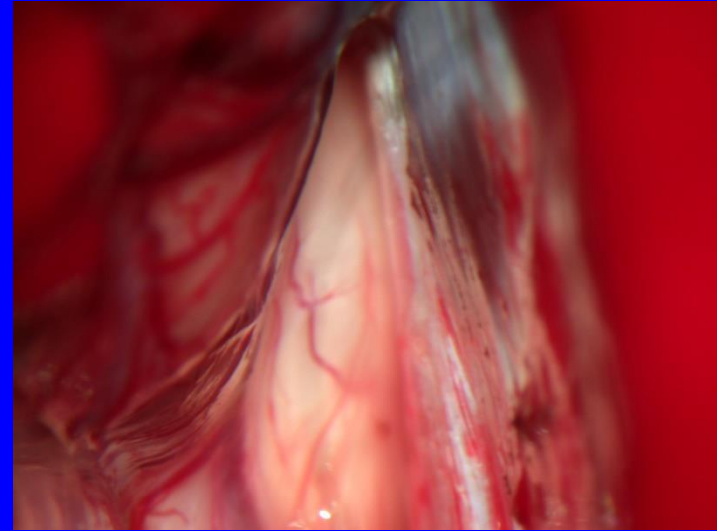
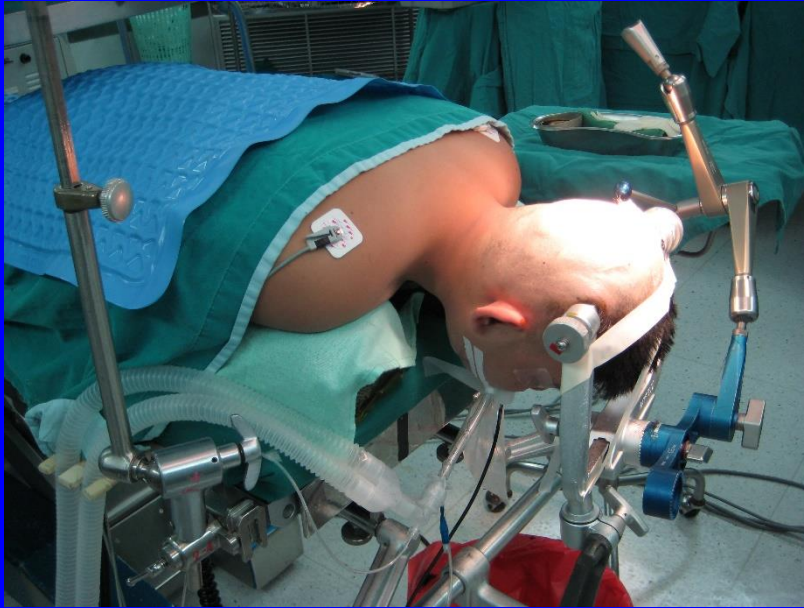
Corpus callosotomy

- Palliative surgery
- Indications
 - Drop attacks (atonic, tonic, GTC)
 - Lennox-Gastaut syndrome
 - Infantile spasms
 - Multiple independent spike foci
 - Refractory idiopathic generalized epilepsy

Anterior corpus callosotomy



Posterior corpus callosotomy



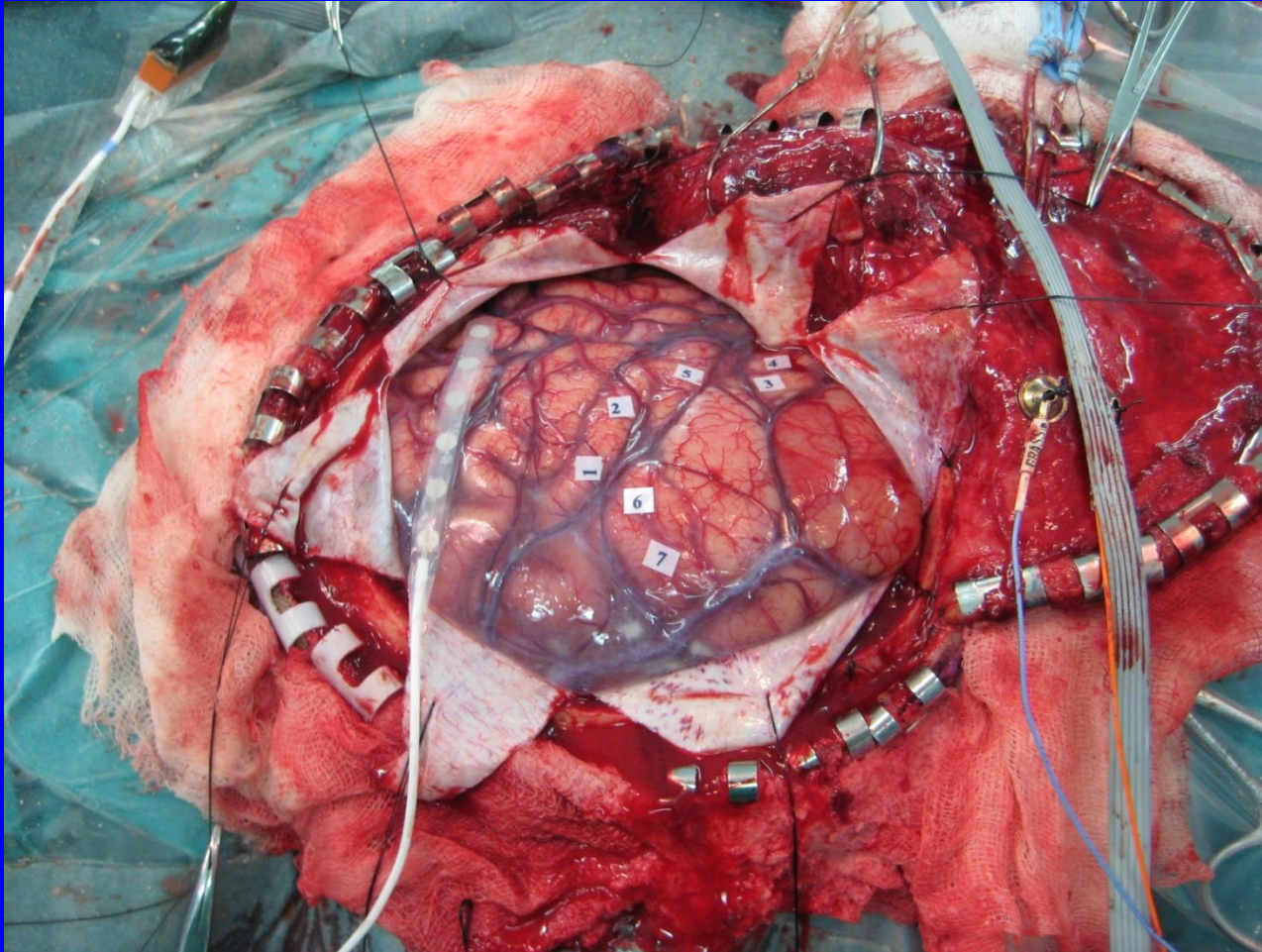
Invasive EEG

- Sphenoidal electrodes
- Epidural electrodes
- Subdural strip/ Grid
- Depth electrodes
- Stereoelectrocorticography (SEEG)

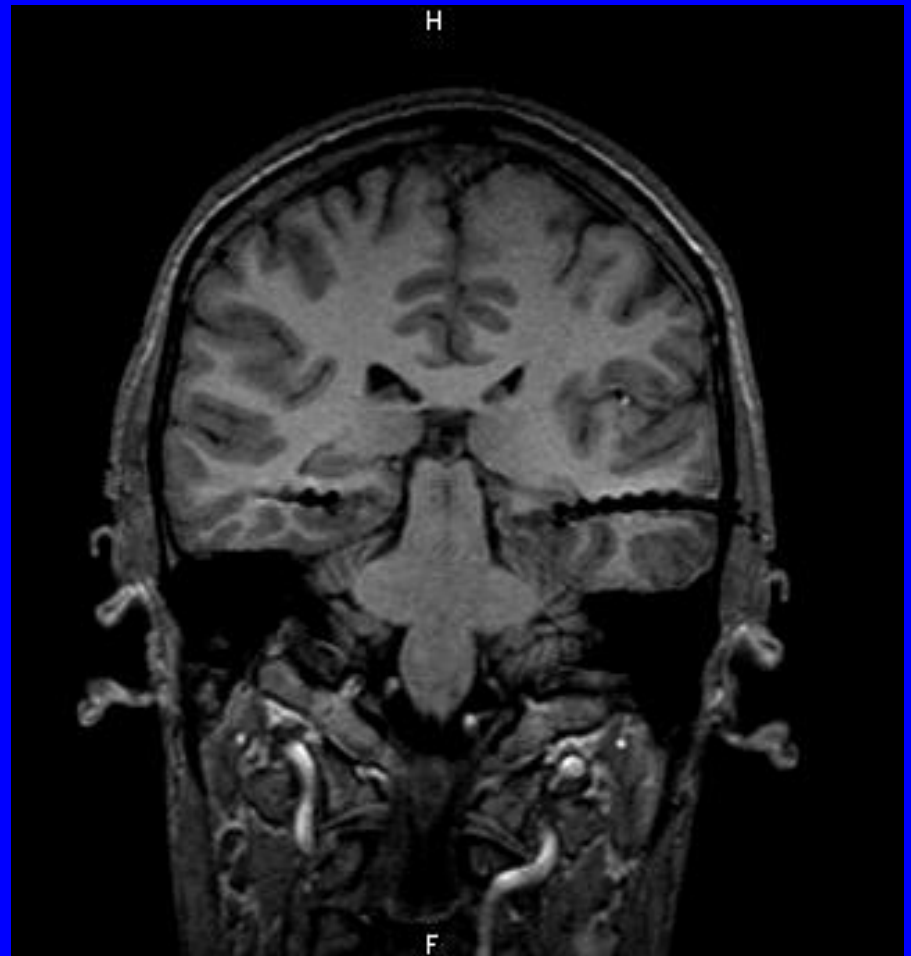
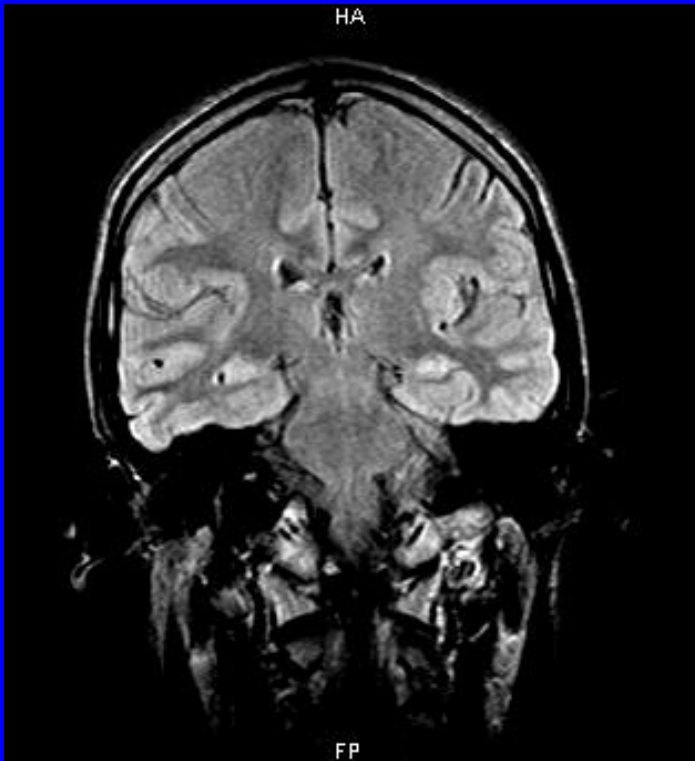
Indications

- Nonconcordant, Nonlocalized
- Extent of resection
- Mapping functional cortex

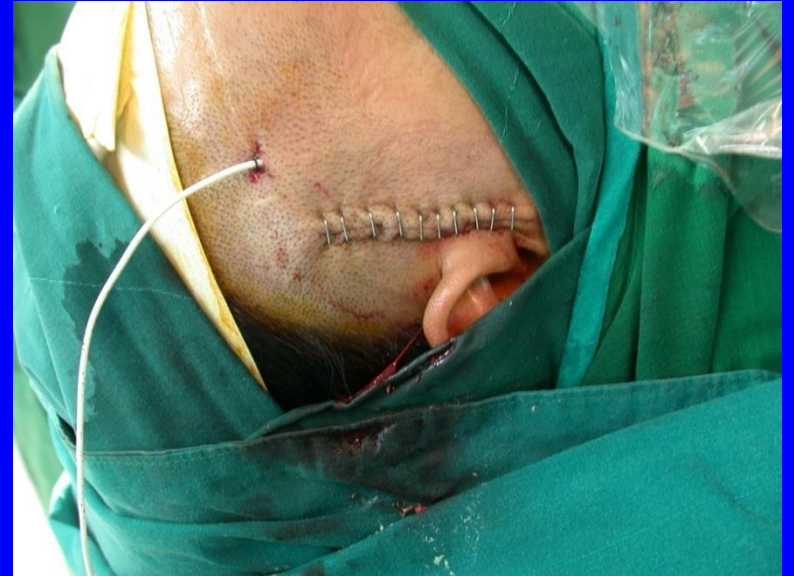
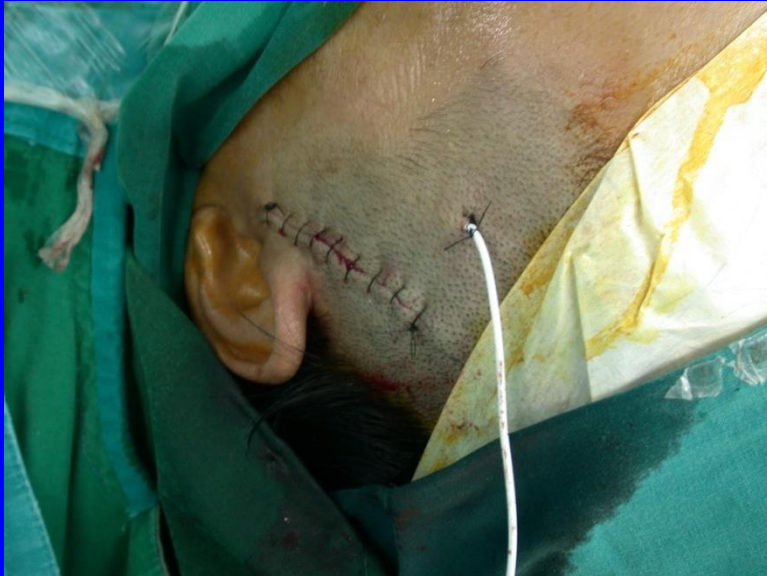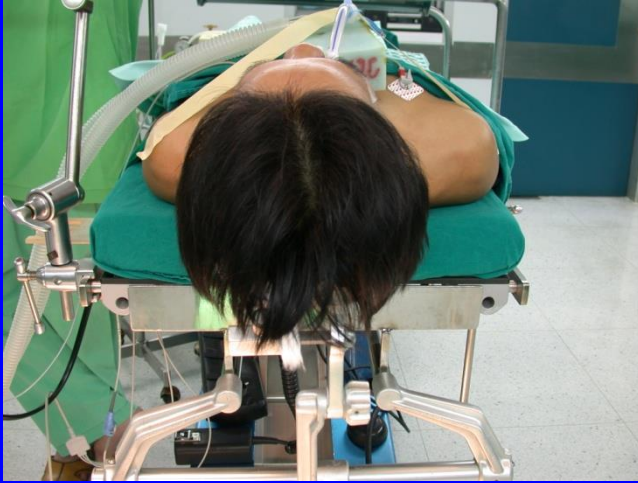Intraoperative ECoG



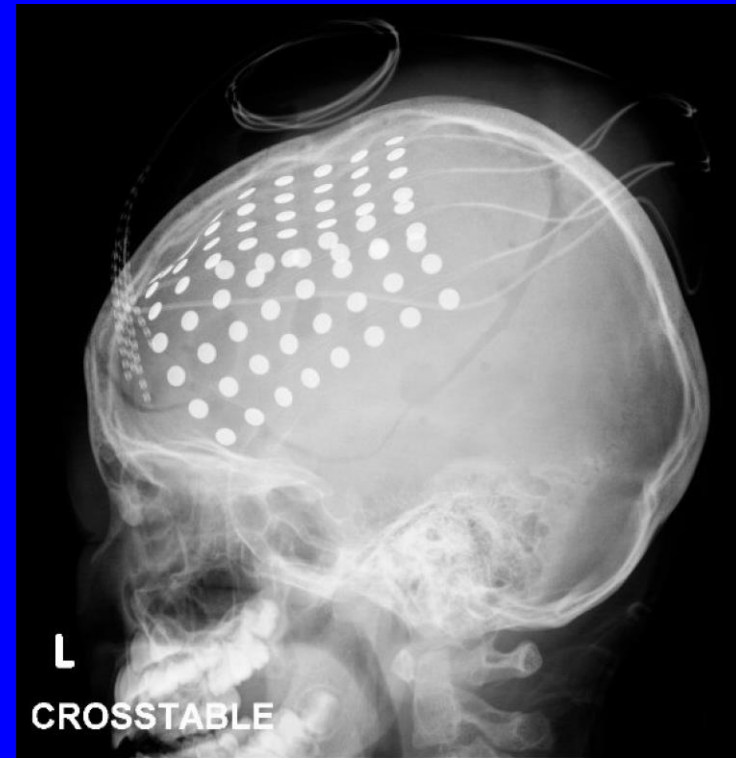
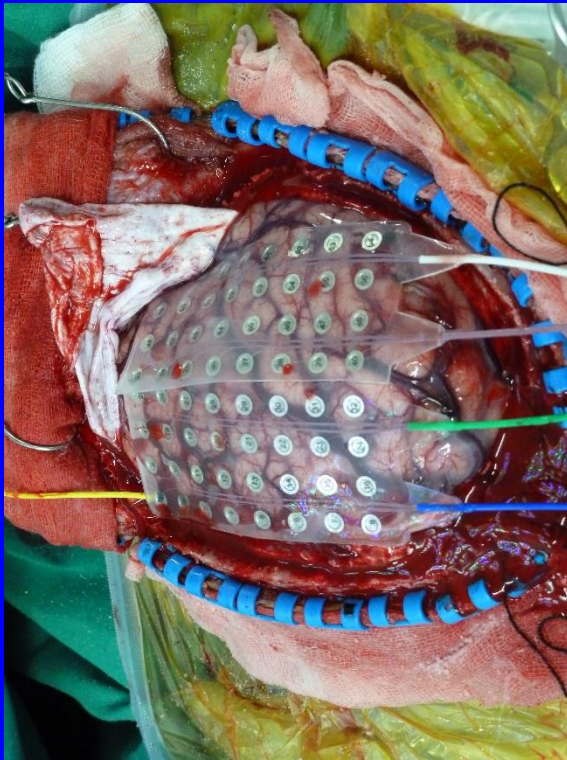
Depth electrodes



Bitemporal subdural strips



Subdural electrode



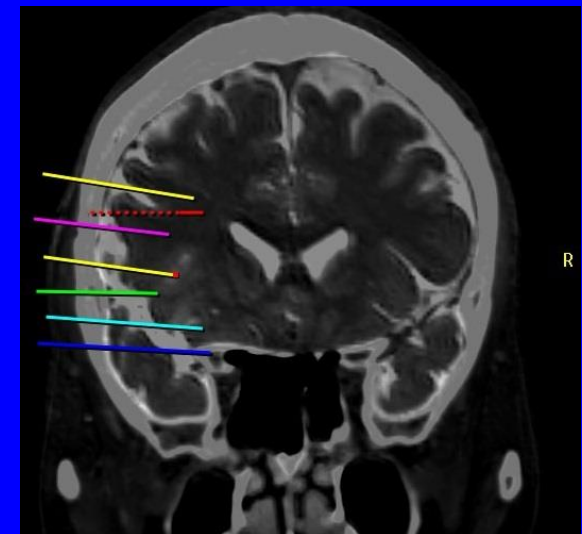
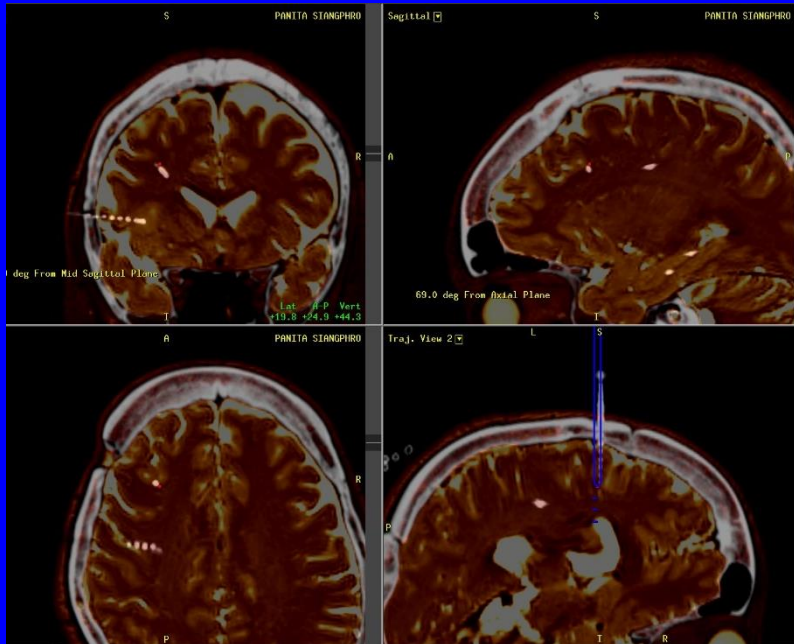
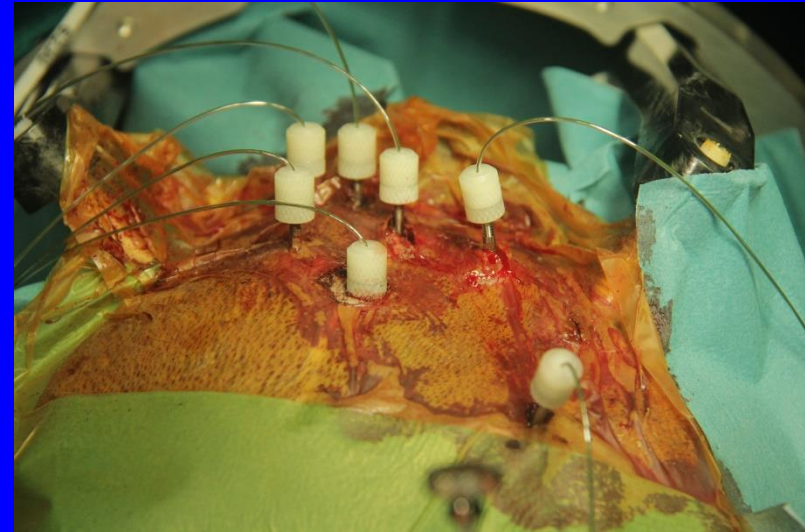
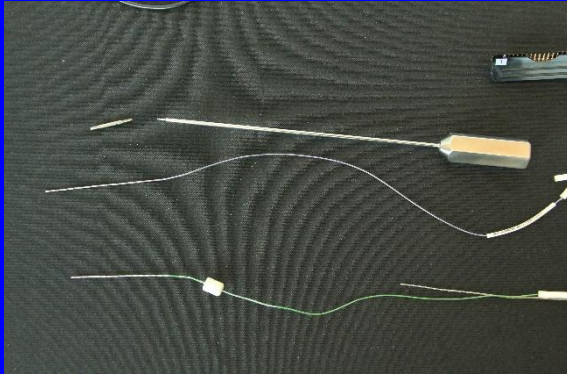
Advantages and disadvantages of the different modalities of invasive monitoring

Invasive modality	Advantages	Disadvantages
Depth electrodes	<ul style="list-style-type: none">• Stereotaxic placement of contacts• Accurate lateralization and localization• Interictal and ictal recordings	<ul style="list-style-type: none">• Increased morbidity• Limited region of study• Unable to map eloquent area
Grid/strip electrodes	<ul style="list-style-type: none">• Easier to implant with direct visualization• Covers larger expanses of cortex• Lesser morbidity compared to depth electrodes• Mapping of eloquent areas of cortex through cortical stimulation	<ul style="list-style-type: none">• Cannot map hippocampus nor amygdala as well as depth electrodes• For SGE, requires craniotomy for placement and removal

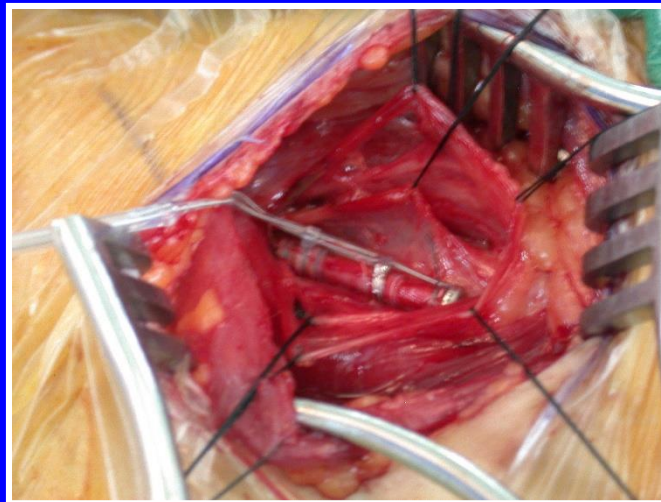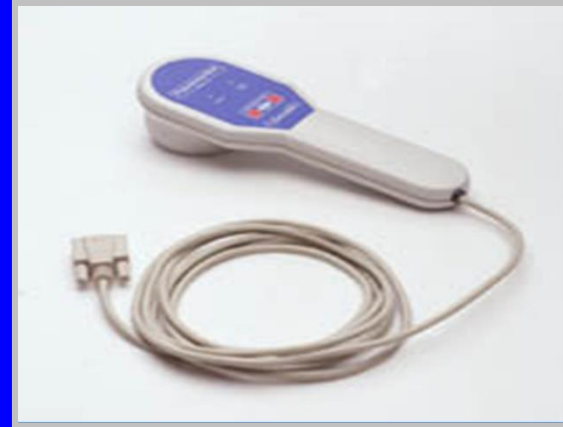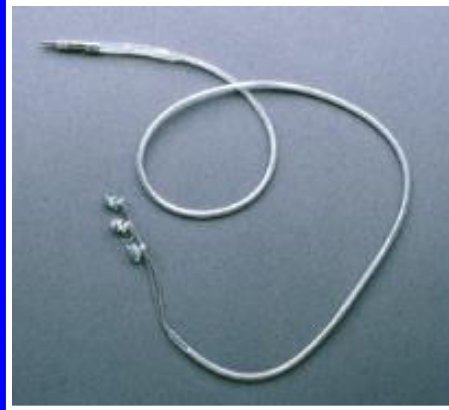Advantages and disadvantages of the different modalities of invasive monitoring

Invasive modality	Advantages	Disadvantages
Intraoperative EcoG	<ul style="list-style-type: none">• No long-term hospital stay• Mapping of eloquent areas of cortex• Location and distance between electrodes can be changed during the procedure	<ul style="list-style-type: none">• Interictal recording only• Long operating room time• Impractical in young children

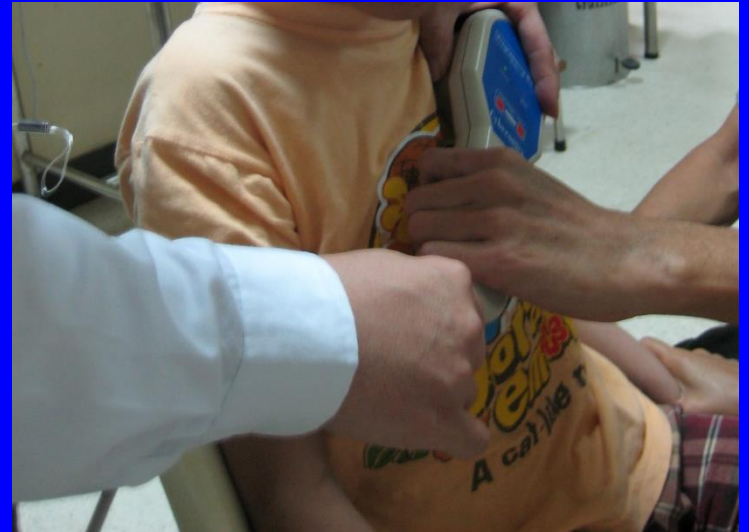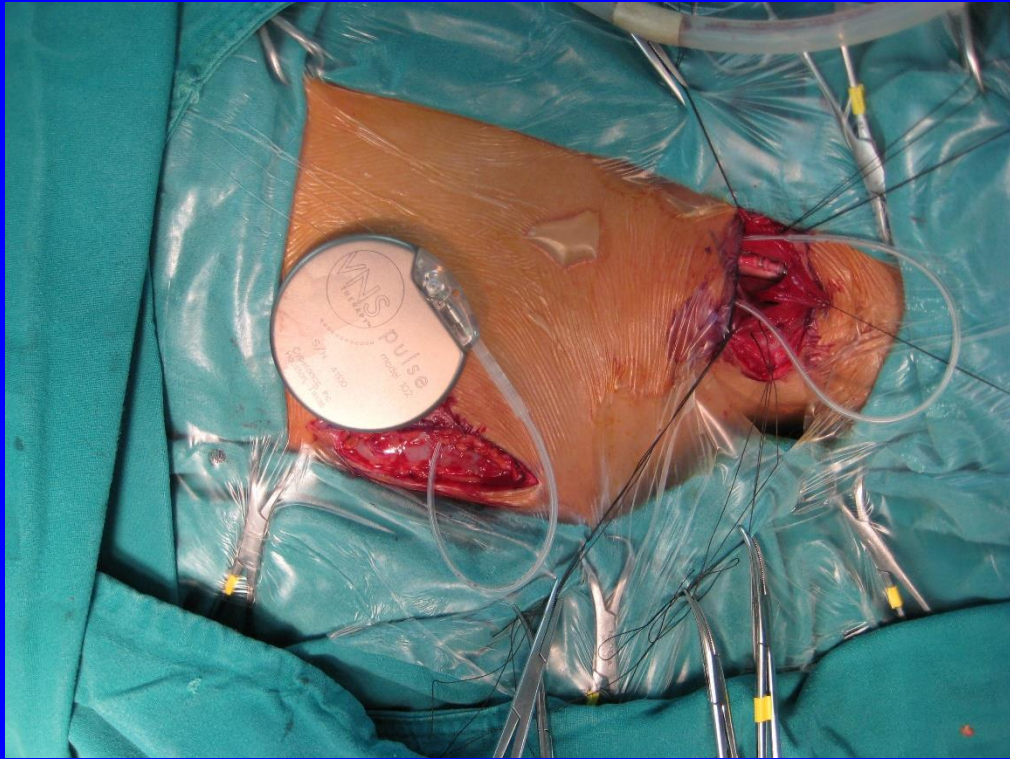
SEEG



VNS



VNS



Outcome after surgery

- Seizure outcome
- Quality of life outcome
- Psychiatric outcome
- Psychosocial outcome

Seizure outcome after epilepsy surgery (Engel's classification)

- **Class I: Free of disabling seizures**
 - A: Completely seizure free since surgery
 - B: Nondisabling simple partial seizures only since surgery
 - C: Some disabling seizures after surgery, but free of disabling seizures for ≥ 2 years
 - D: Generalized convulsions with AED withdrawal only
- **Class II: Rare seizures (“almost seizure-free”)**
 - A: Initially free of disabling seizures but has rare seizure now
 - B: Rare disabling seizures since surgery
 - C: More than rare disabling seizures since surgery but rare seizures for the last 2 years
 - D: Nocturnal seizures only

Engel's classification

- **Class III: Worthwhile improvement**

- A: Worthwhile seizure reduction

- B: Prolonged seizure-free intervals amounting to greater than half the follow-up period, but not \leq 2 years

- **Class IV: No worthwhile improvement**

- A: Significant seizure reduction

- B: No appreciable change

- C: Seizures worse

ILAE Classification

1: Completely seizure free; no aura

1a: Completely seizure free since surgery

2: Only auras; no aura other seizures

3: One to three seizure days per year, \pm auras

4: Four seizure days per year to 50% reduction of baseline seizure days; \pm auras

5: Less than 50% reduction of baseline seizure days to 100% increase of baseline seizure days; \pm auras

6: More than 100% increase of baseline seizure days; \pm auras

Surgery: long-term outcome

- Meta-analysis of 78 trials on resective epilepsy surgery. Median follow-up > 5 years
- Seizure-free (Engle I)
 - Temporal: n=3895 **66%**
 - Parietal: n=82 46%
 - Occipital: n=35 46%
 - Frontal: n=486 27%
 - Extratemporal: n=169 34%
 - Hemispherectomy: n=169 **61%**
 - Tumor related **76%**

Thank you